A expressão de proteínas pela técnica de imuno-histoquímica em doenças infecciosas

Carla Pagliari

cpagliari@usp.br

Imuno-histoquímica: etapas

- Coleta, preservação e fixação
- Processamento e obtenção dos cortes
- Bloqueio da peroxidase endógena
- Recuperação antigênica
- Incubação com anticorpos primários
- Incubação com anticorpos secundários
- Sistema de revelação da reação

Laboratório DPMT
Disciplina de Patologia de Moléstias Transmissíveis
Faculdade de Medicina da USP

- **Protocolo Lab. da Disciplina de Patologia de Moléstias Transmissíveis – FMUSP**
- **“Como eu faço”:**
  - Desparafinização – 20 minutos t.a.
  - Hidratação – sequencia decrescente de etanol – 5 minutos cada
  - Água corrente / destilada
  - Bloqueio de peroxidase endógena – H_2O_2 2x15 minutos câmara escura
  - Água corrente / destilada / PBS
  - Exposição de antígenos com TRIS/EDTA pH9.0 ou Tampão citrato pH 6.0
    – Banho Maria 95°C – 25 minutos
  - Água corrente / destilada / PBS
  - Incubação com leite desnatado – 30 minutos (opcional)

- **Protocolo Lab. da Disciplina de Patologia de Moléstias Transmissíveis – FMUSP**
- **“Como eu faço”:**

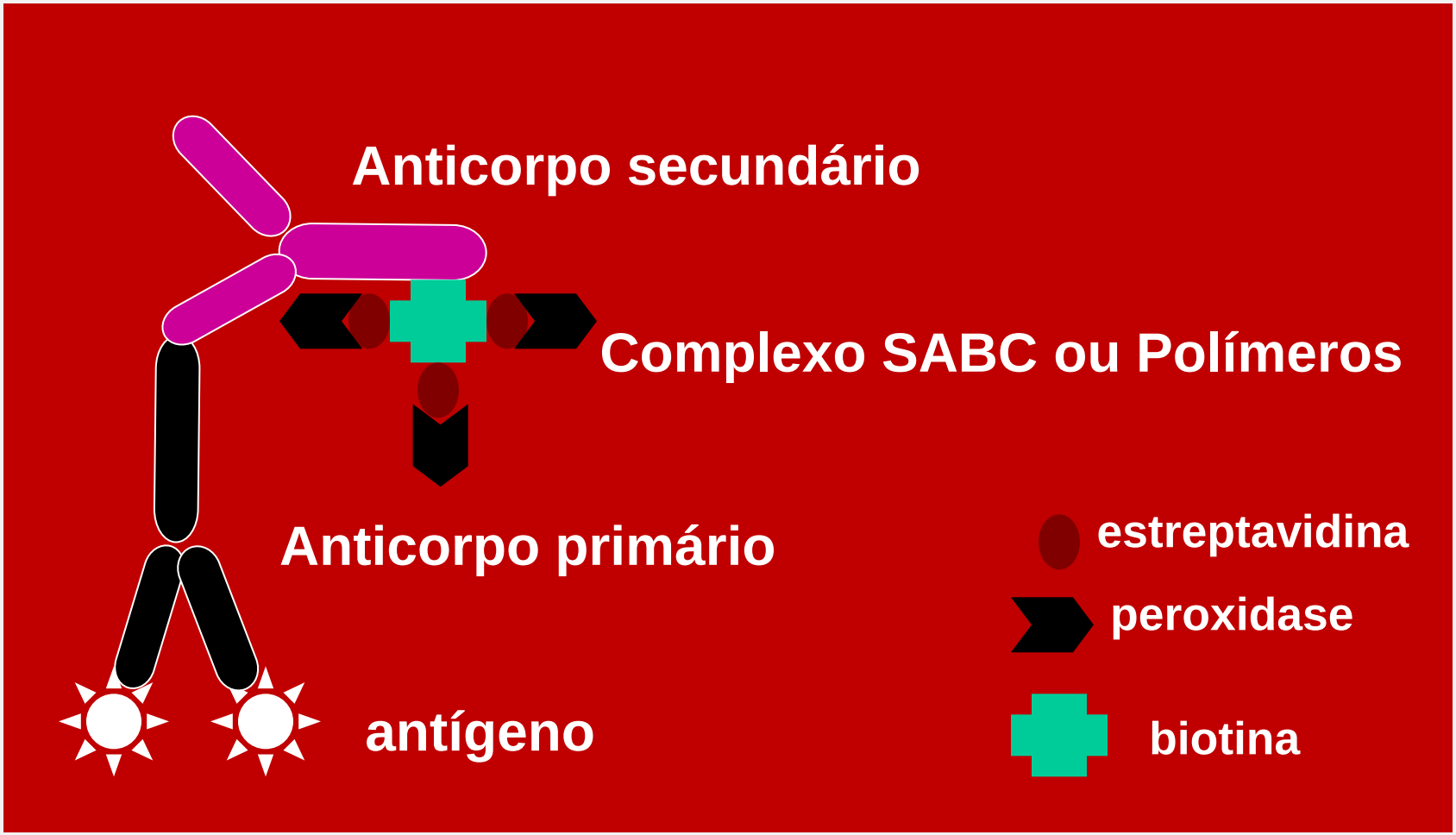

- **Para detecção de citocinas: Lavagem com PBS/saponina 0,1% 10 minutos antes do secundário e terciário**

Imuno-histoquímica e agentes infecciosos

- Especificidade
- Alta sensibilidade
- Anticorpos primários poli ou monoclonais
- Sistemas de detecção sensíveis

Aplicação diagnóstica da imuno-histoquímica

- Identificação específica do agente etiológico
- Demonstração de agentes antes que ocorra resposta característica no tecido
- Evidência de infecção ativa
- Estudos retrospectivos em material parafinado

Citomegalovírus

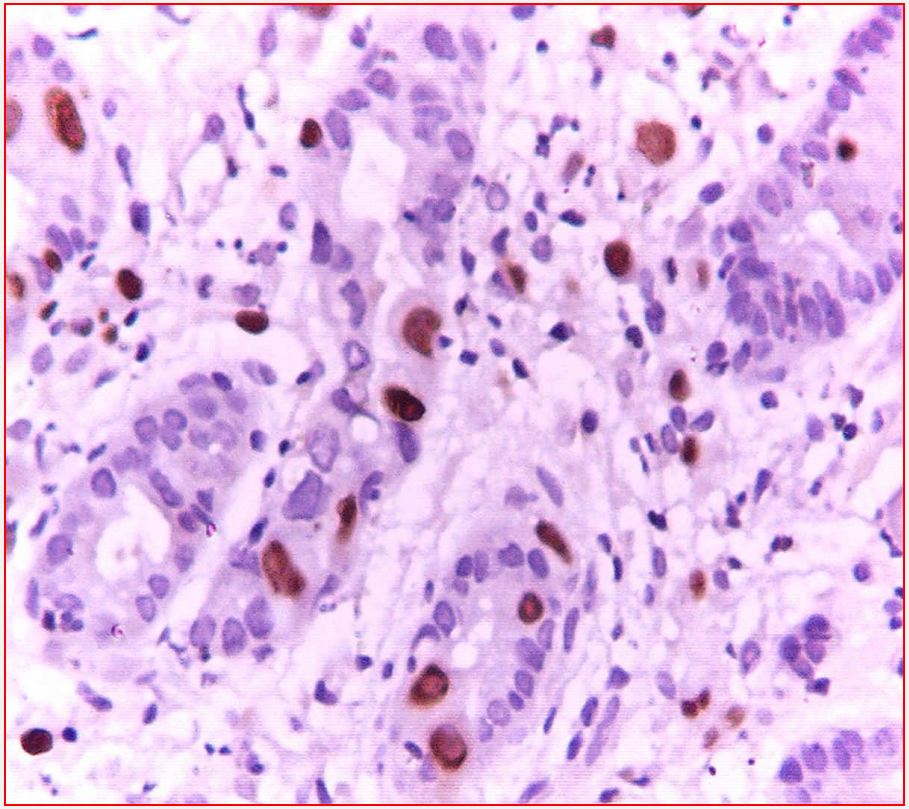

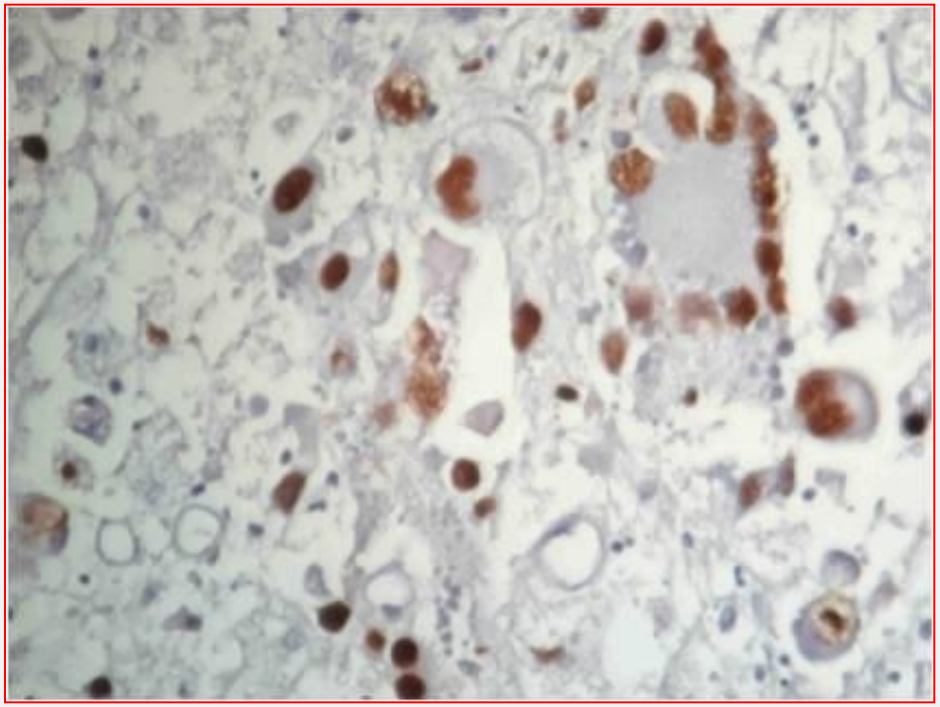

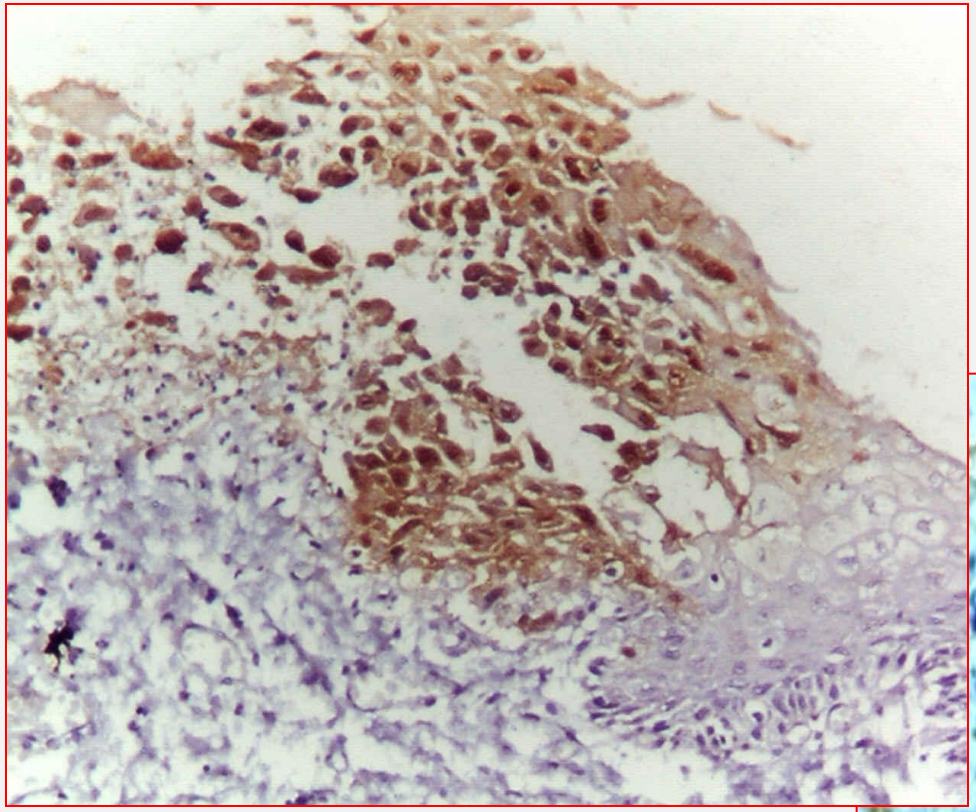

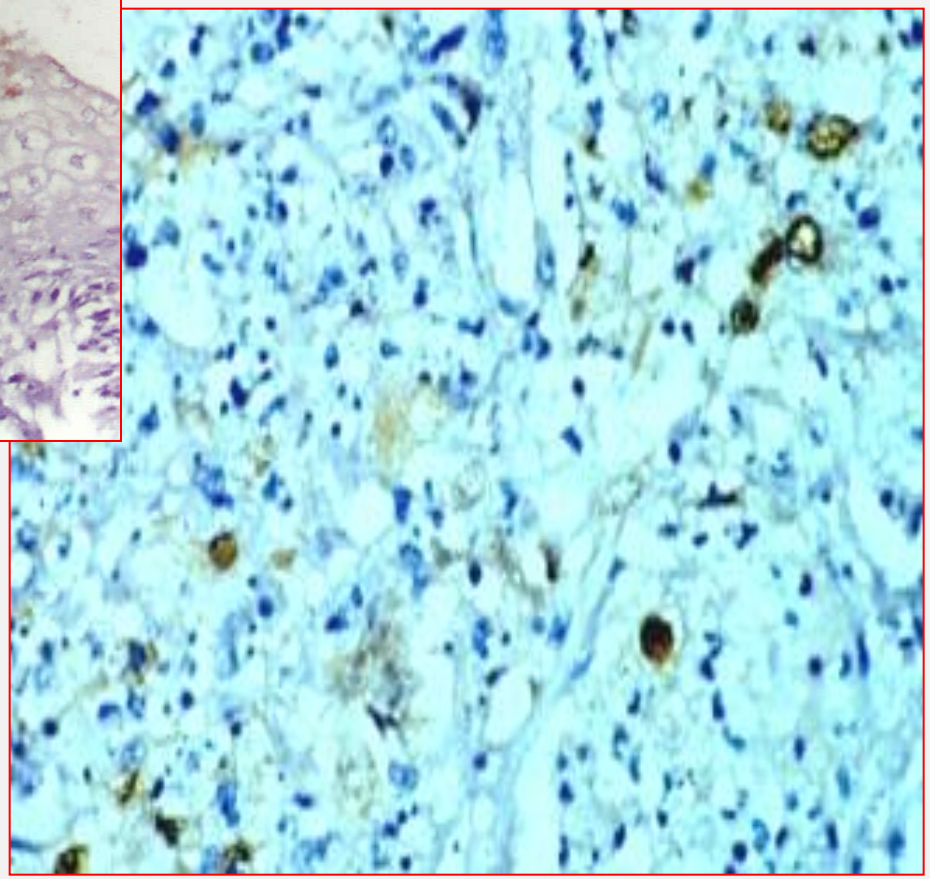

Herpes vírus tipo II

Herpes 8

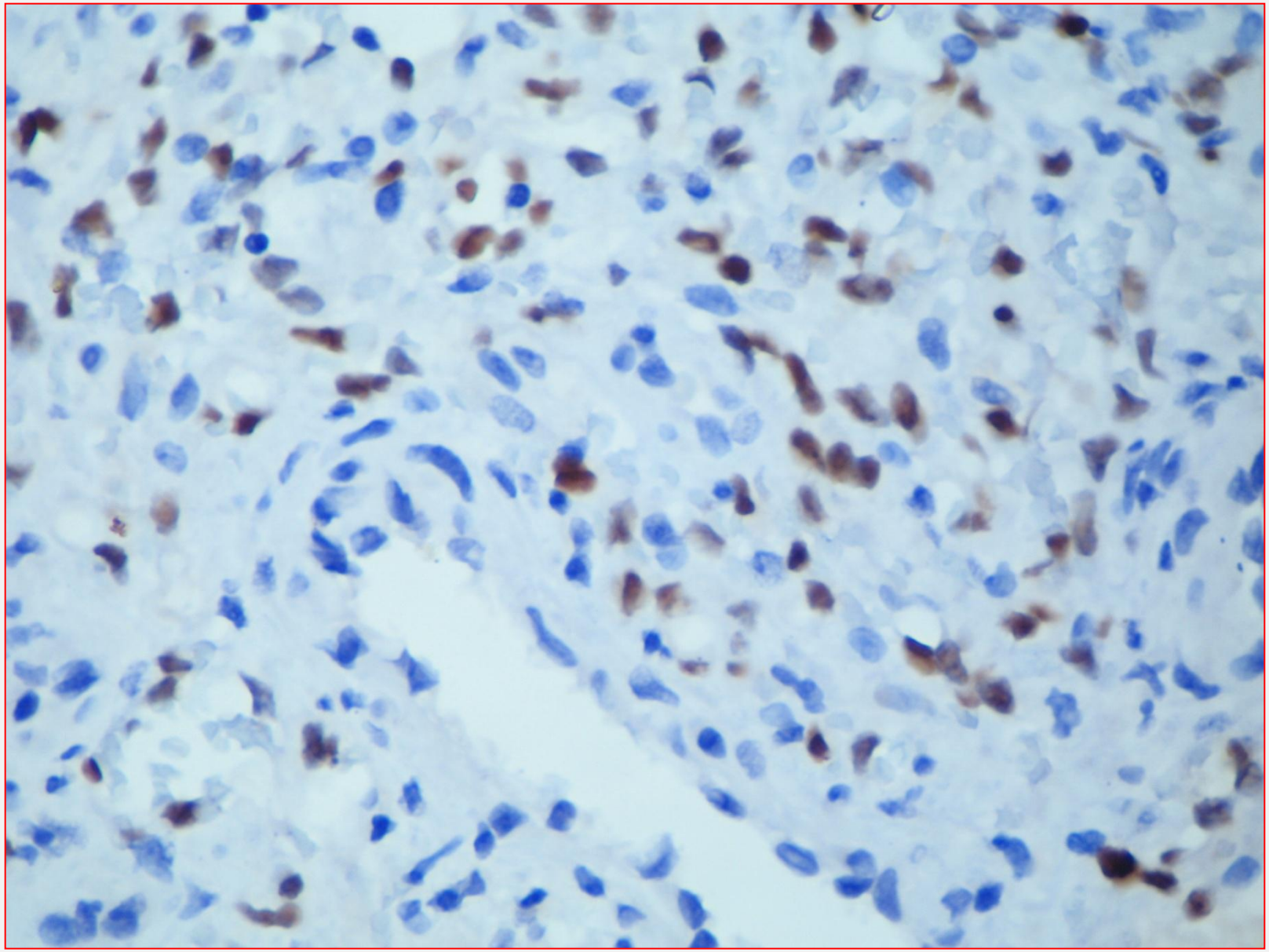

Adenovírus

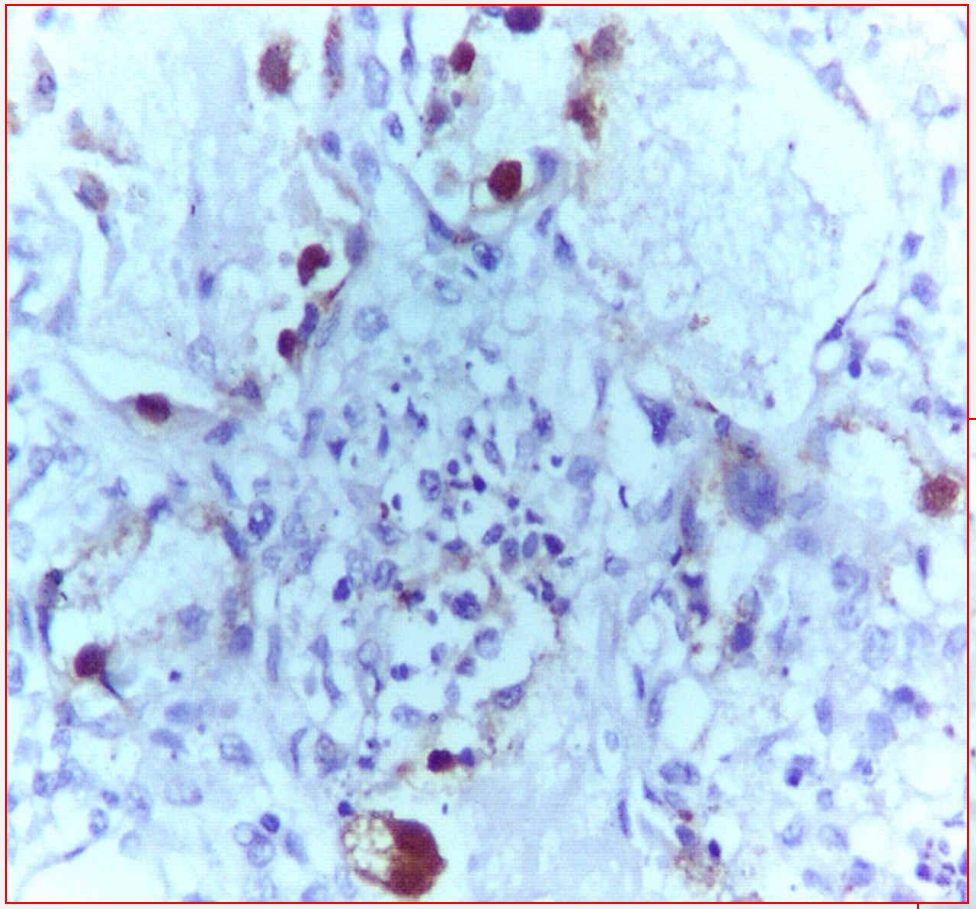

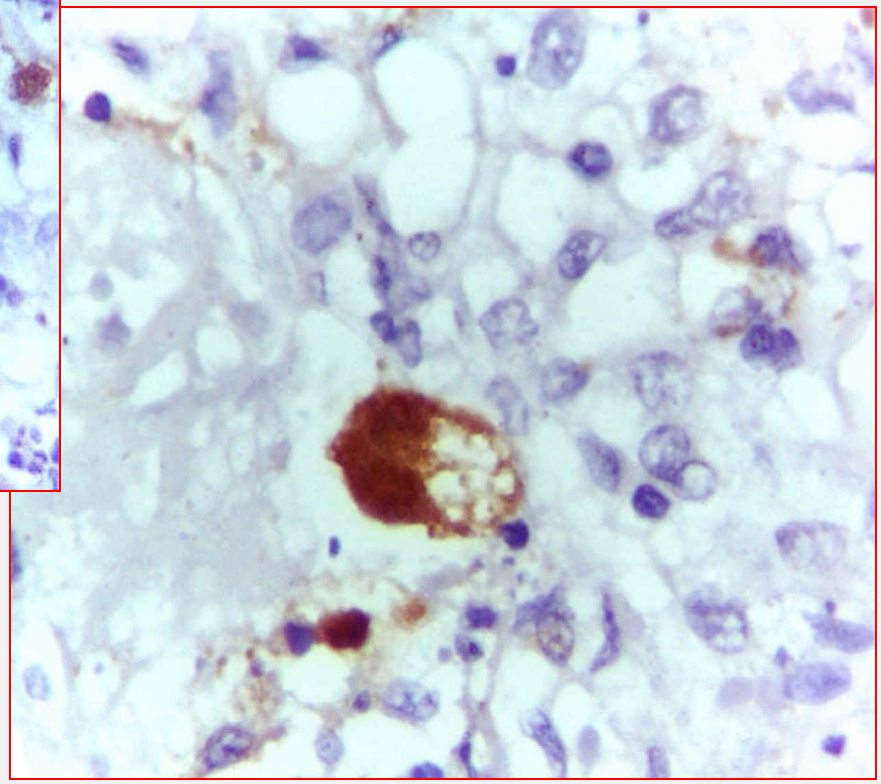

Raiva

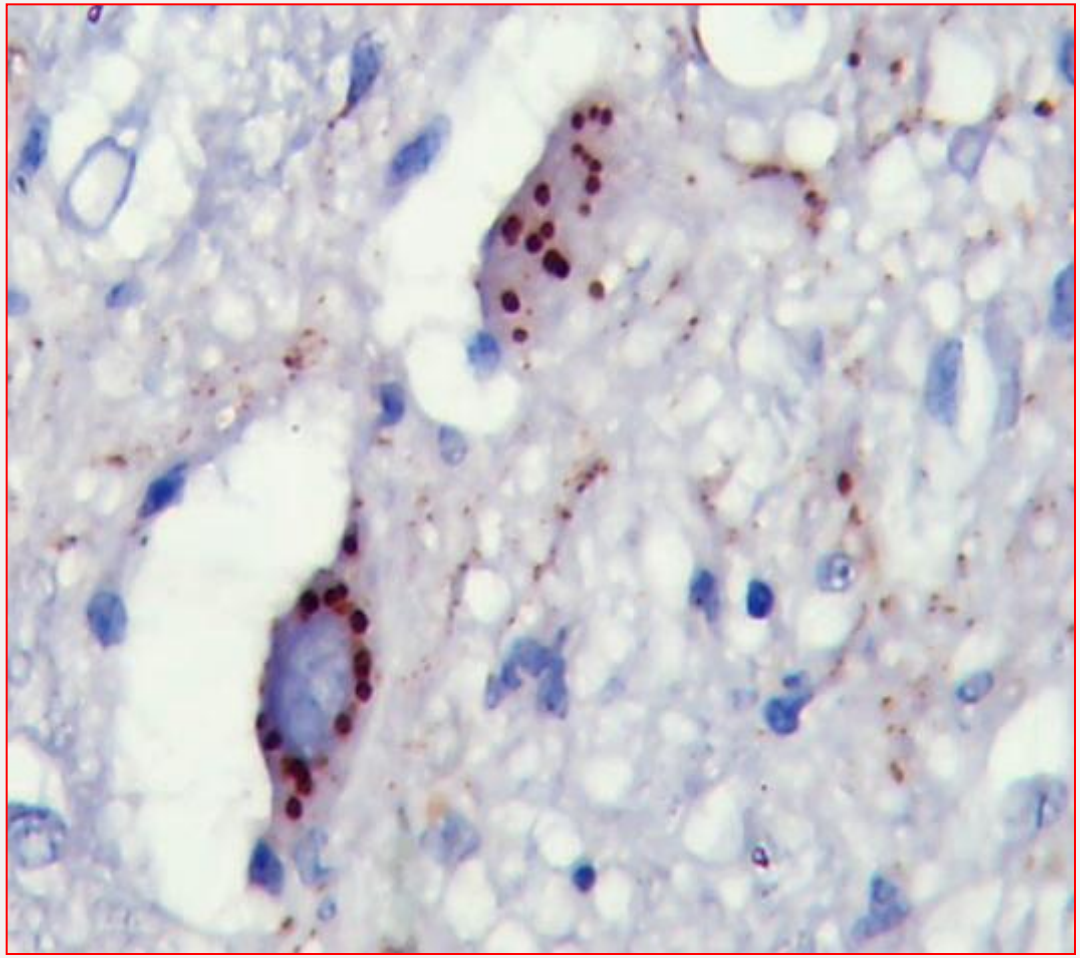

Papilomavirus humano

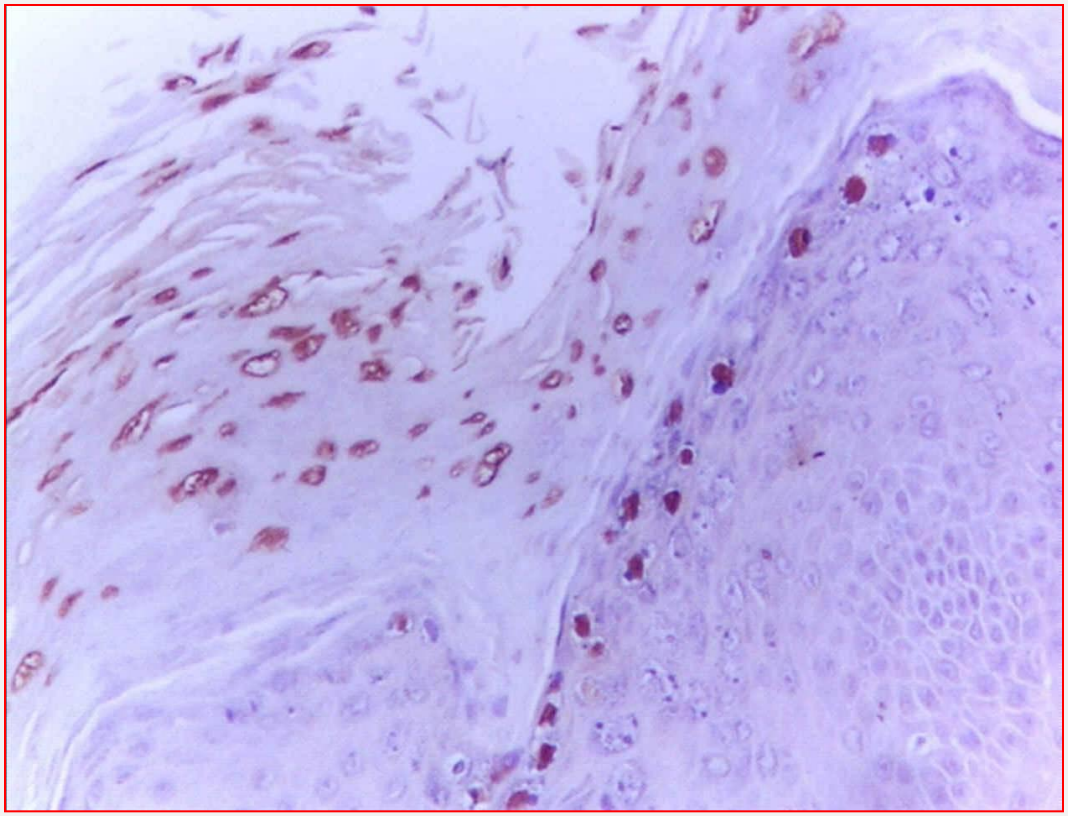

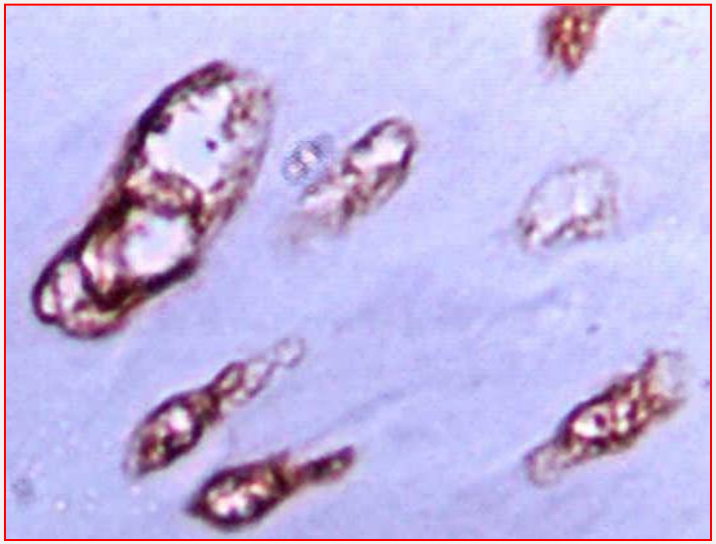

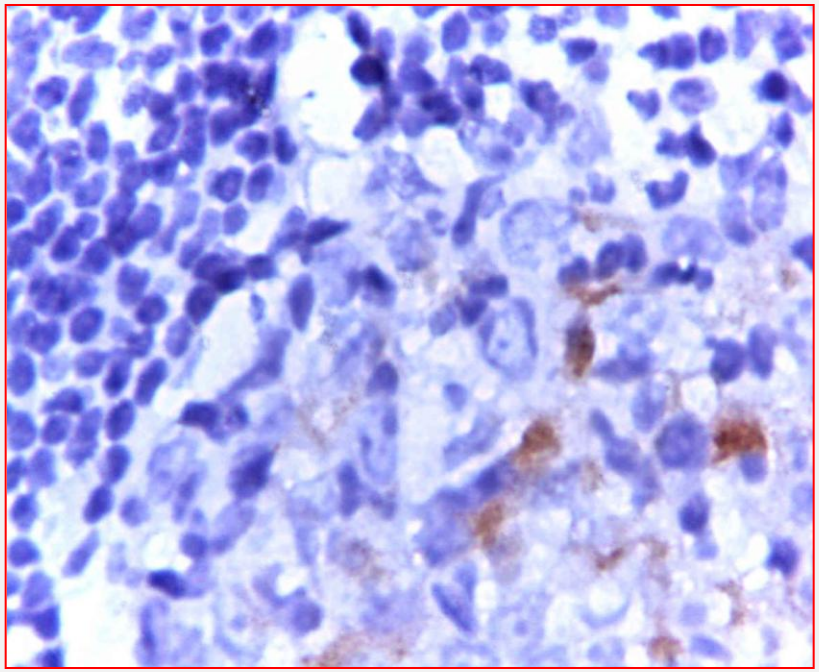

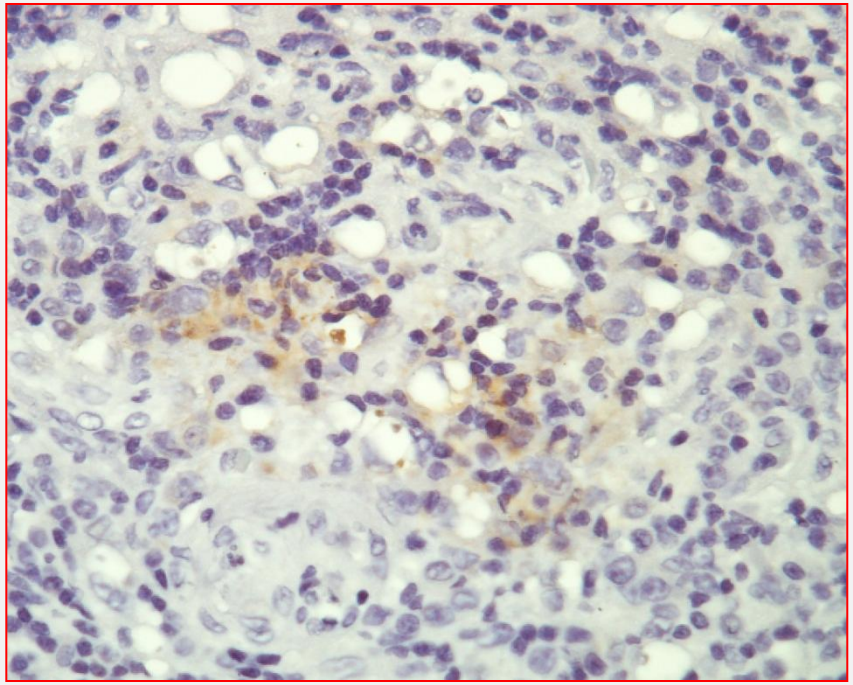

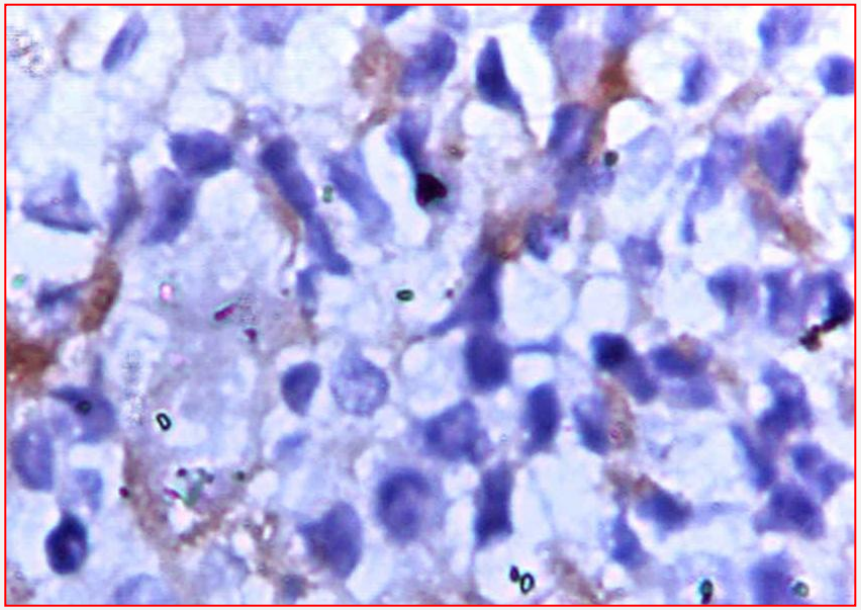

Linfonodo

HIV - p24

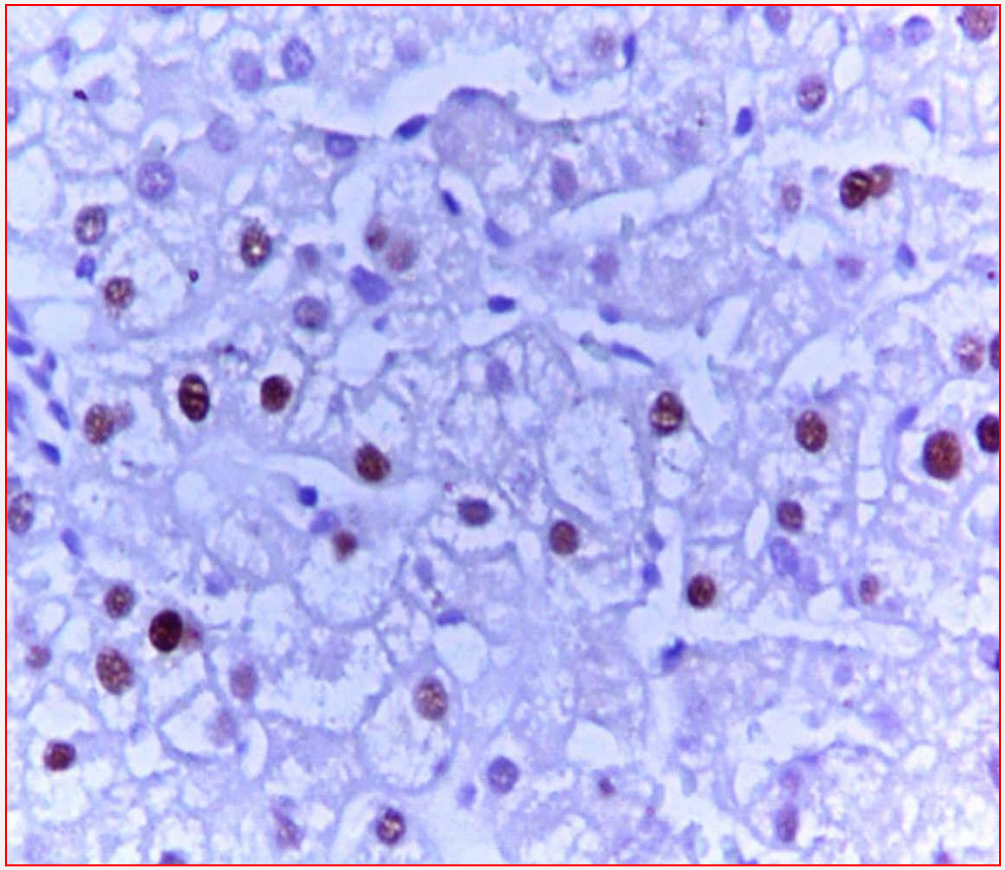

Vírus da hepatite B

Vírus da hepatite B

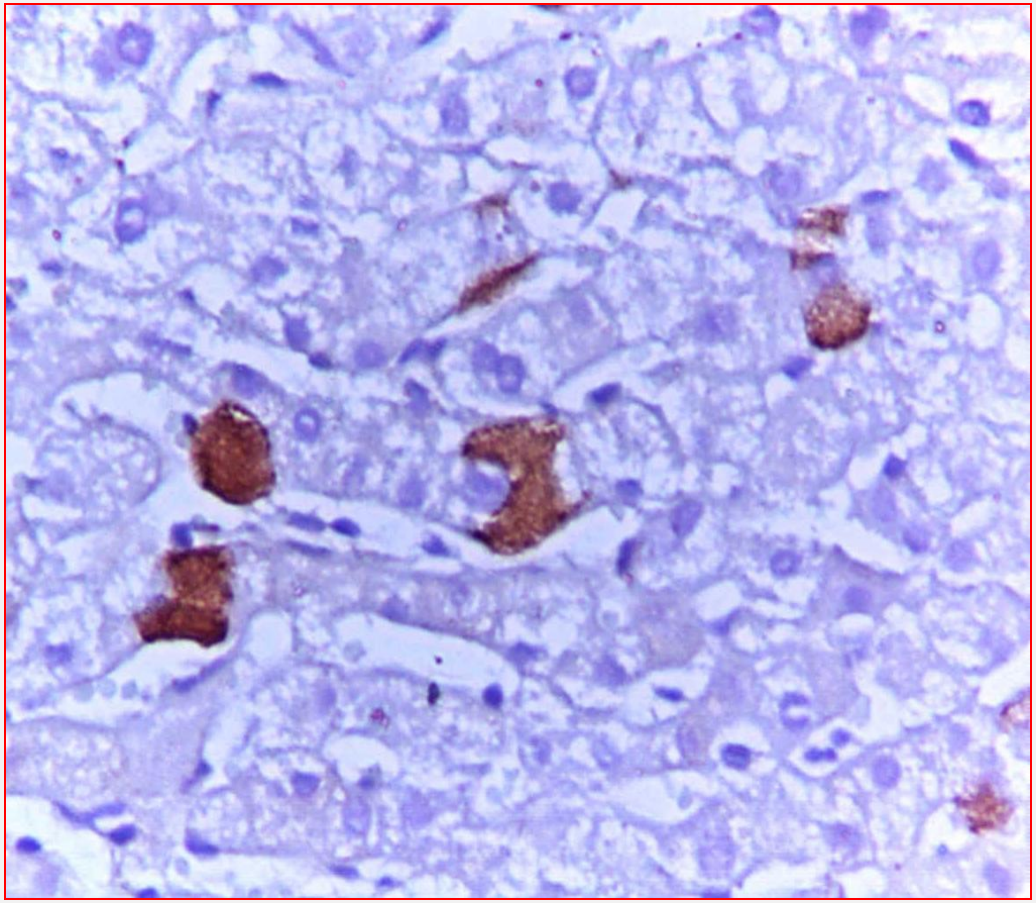

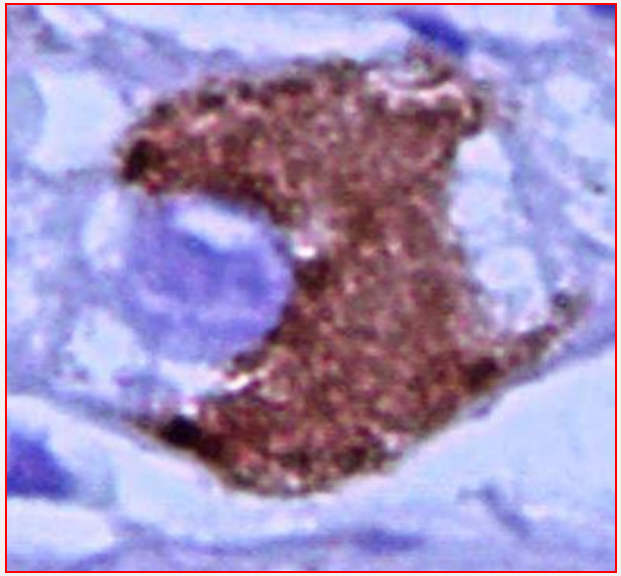

Dengue tipo II

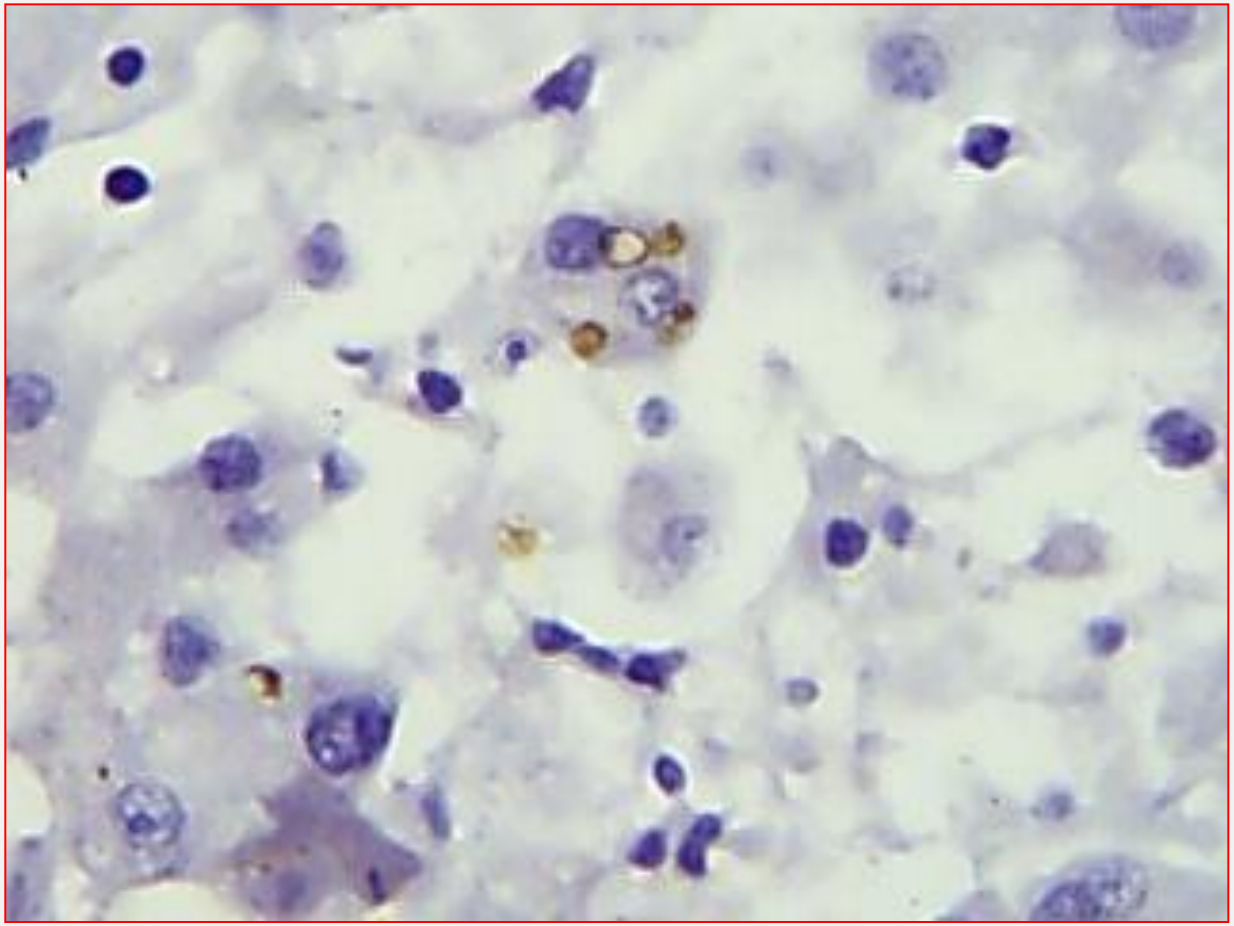

Leptospira

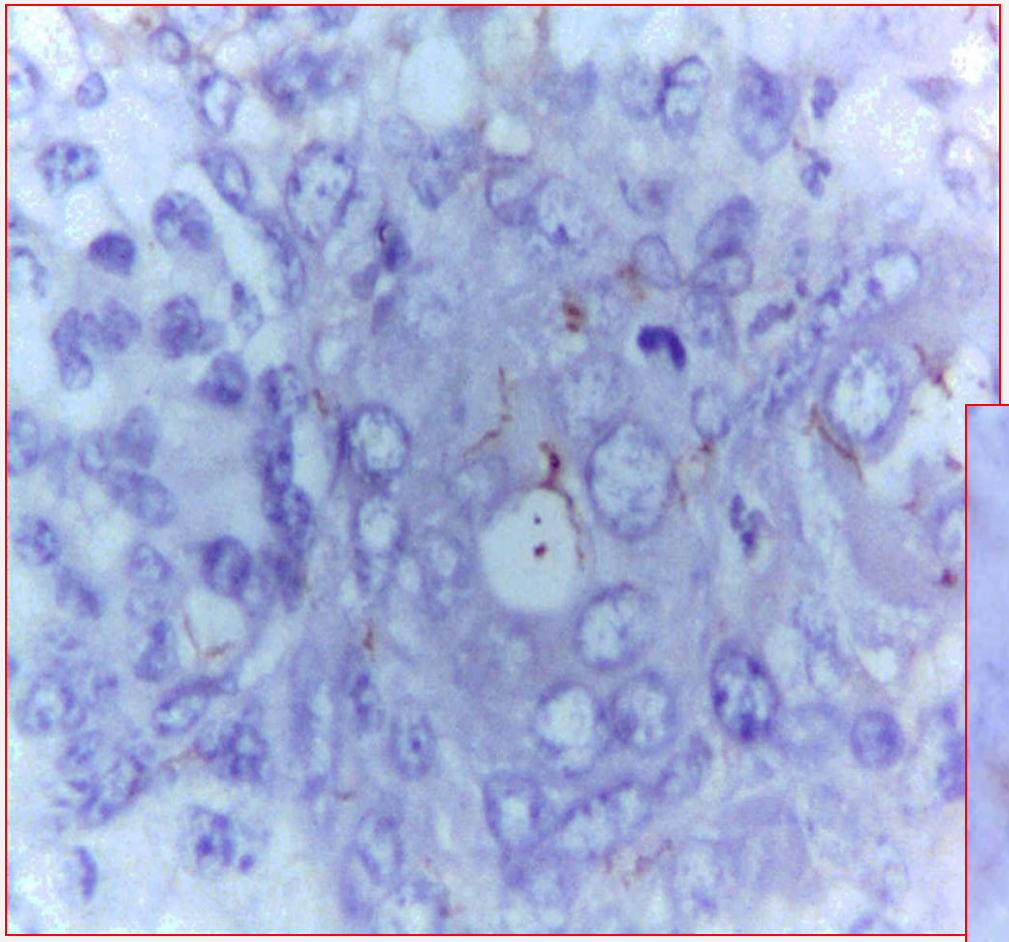

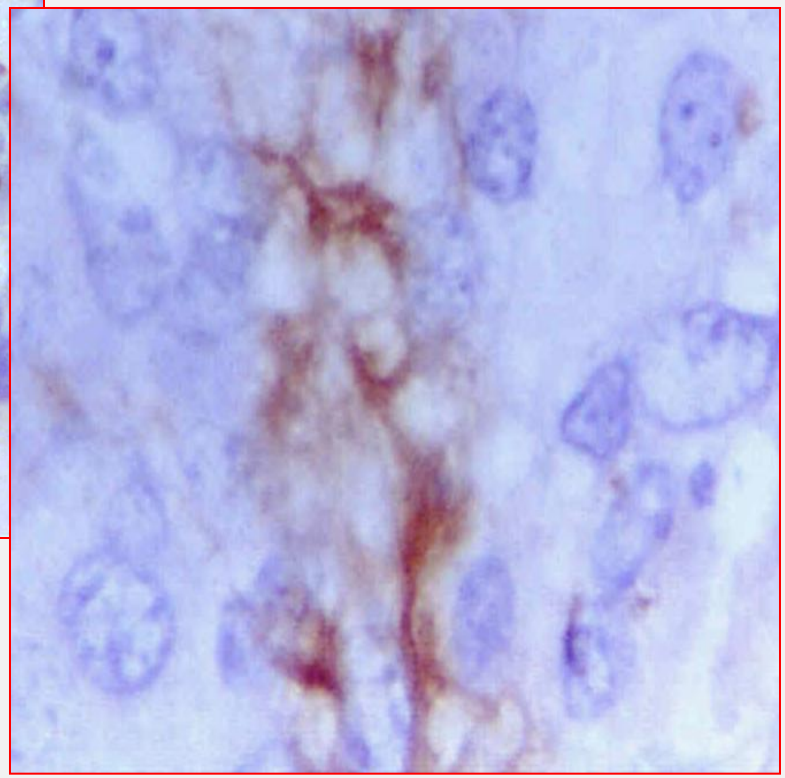

Micobactéria

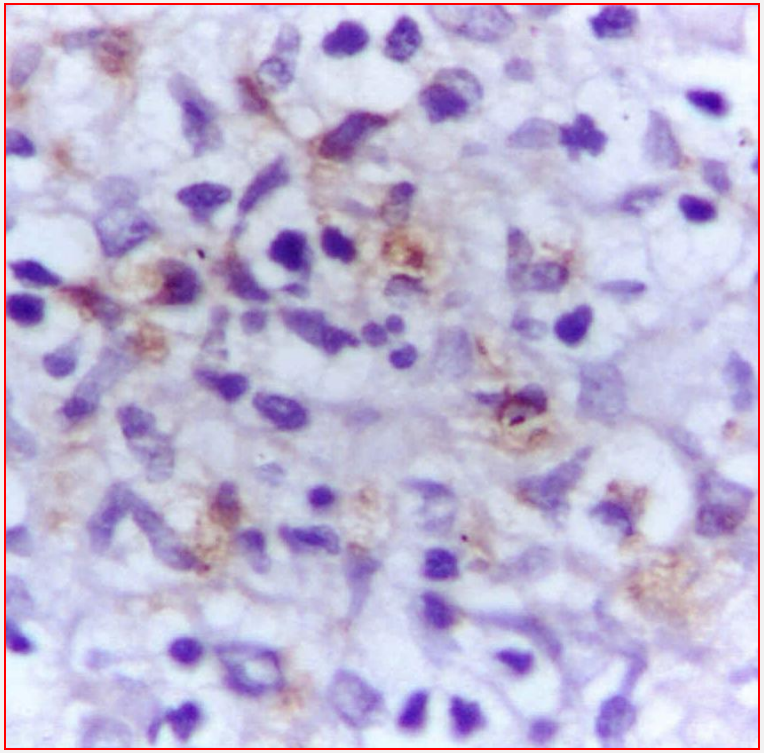

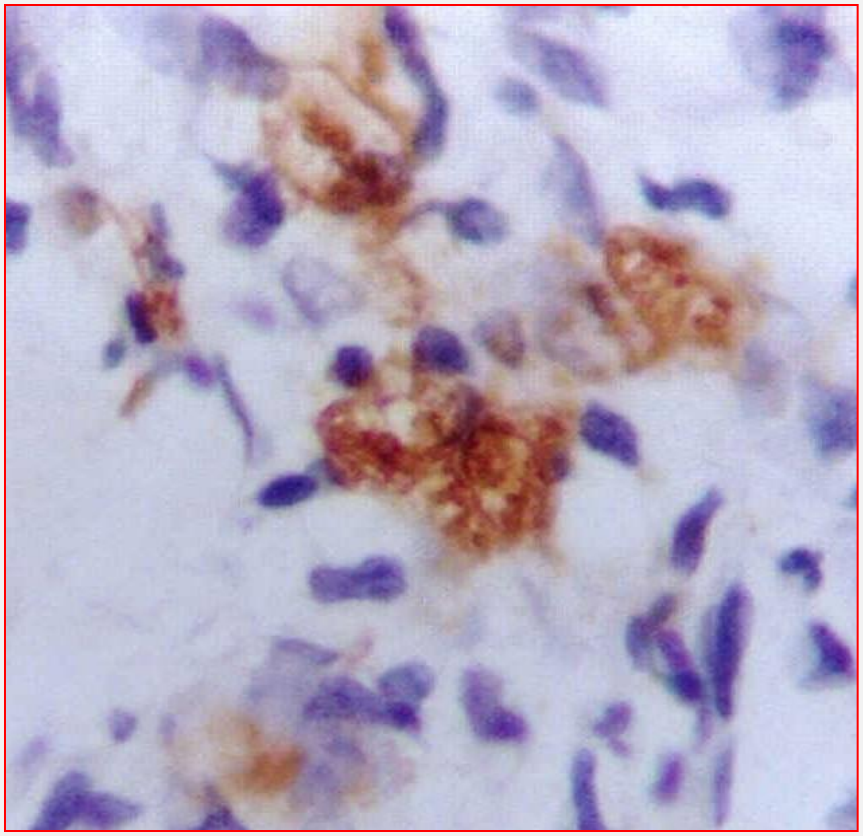

Paracoccidioides brasiliensis

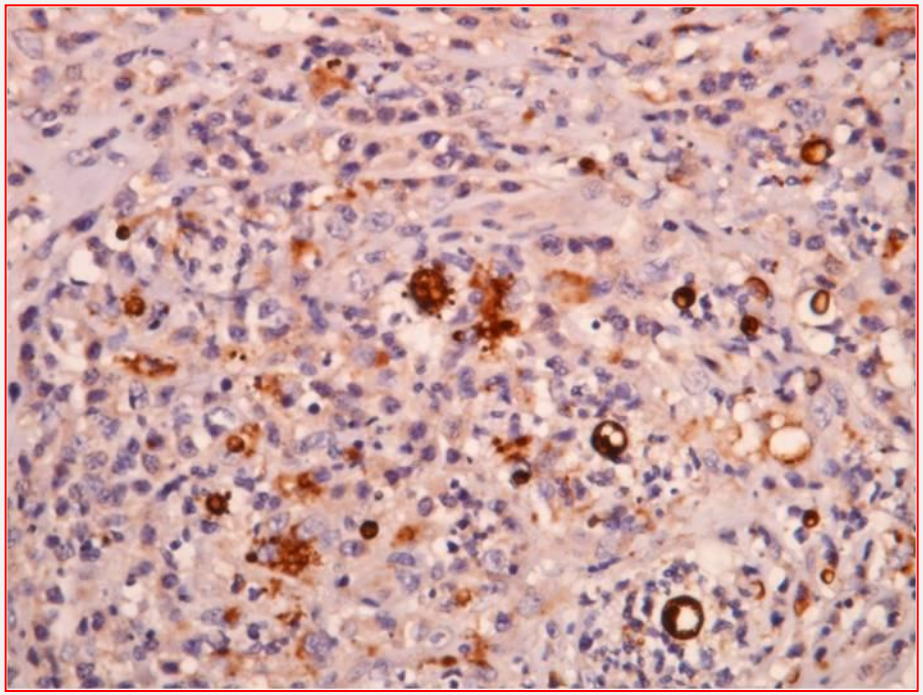

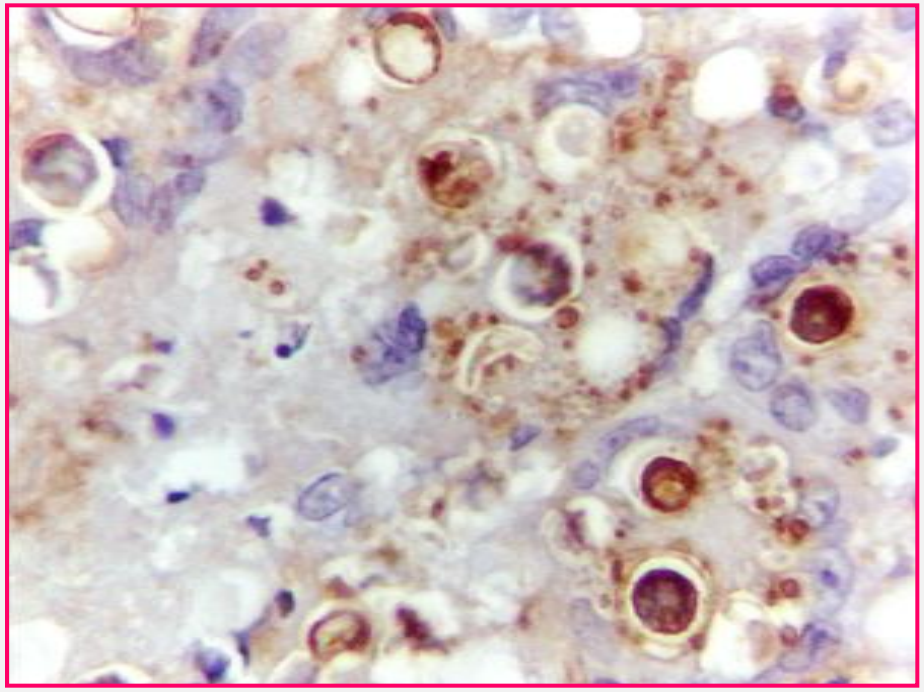

Pneumocystis carinii

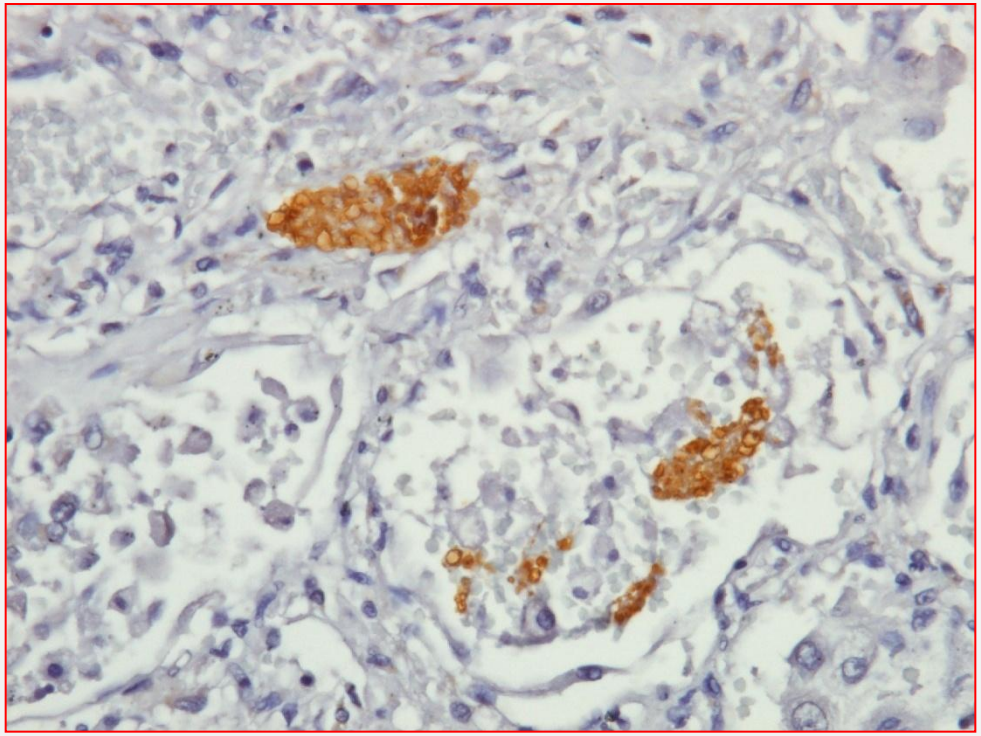

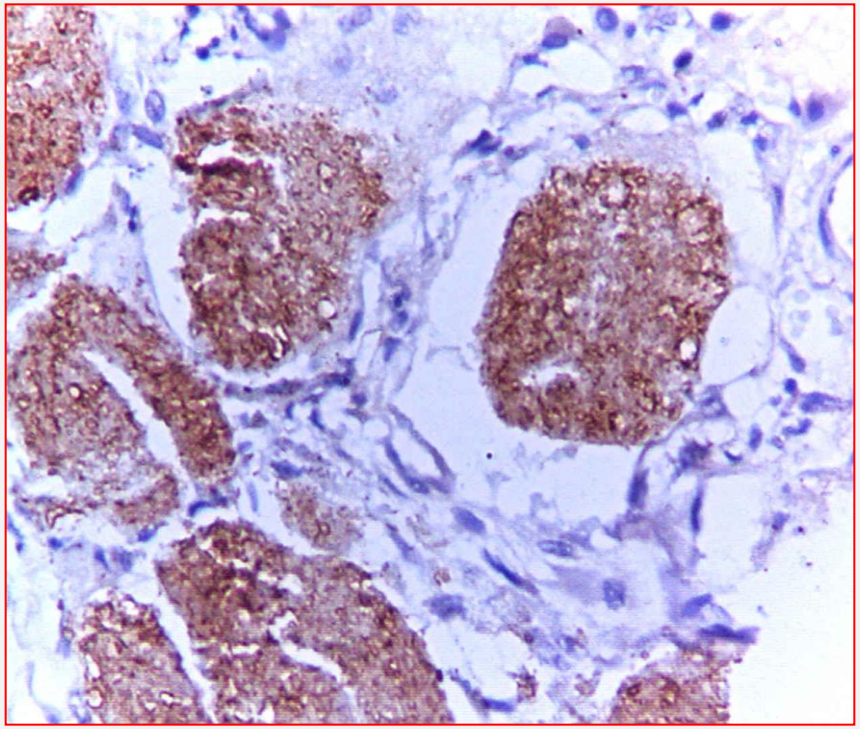

Cryptococcus neoformans

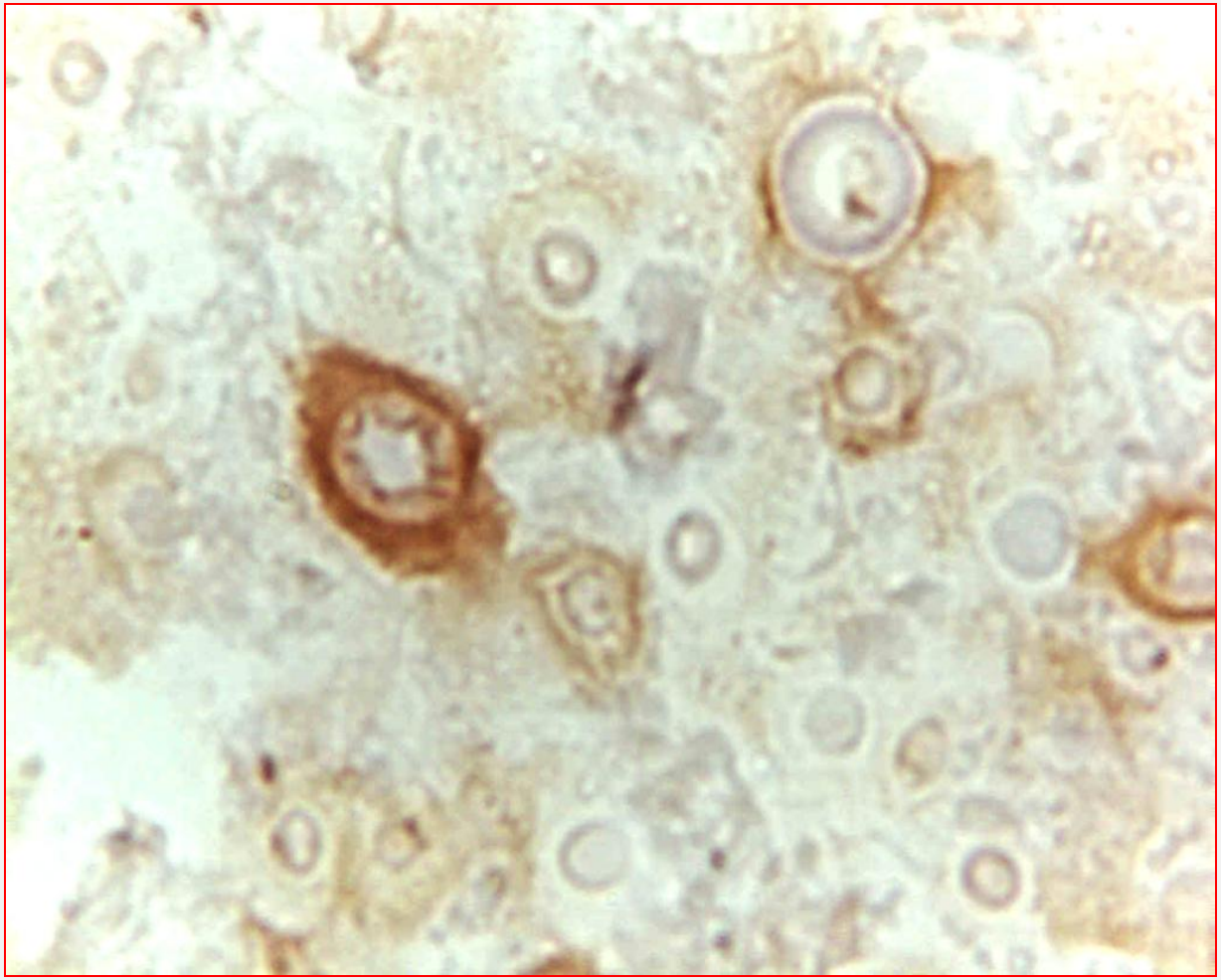

Candida albicans

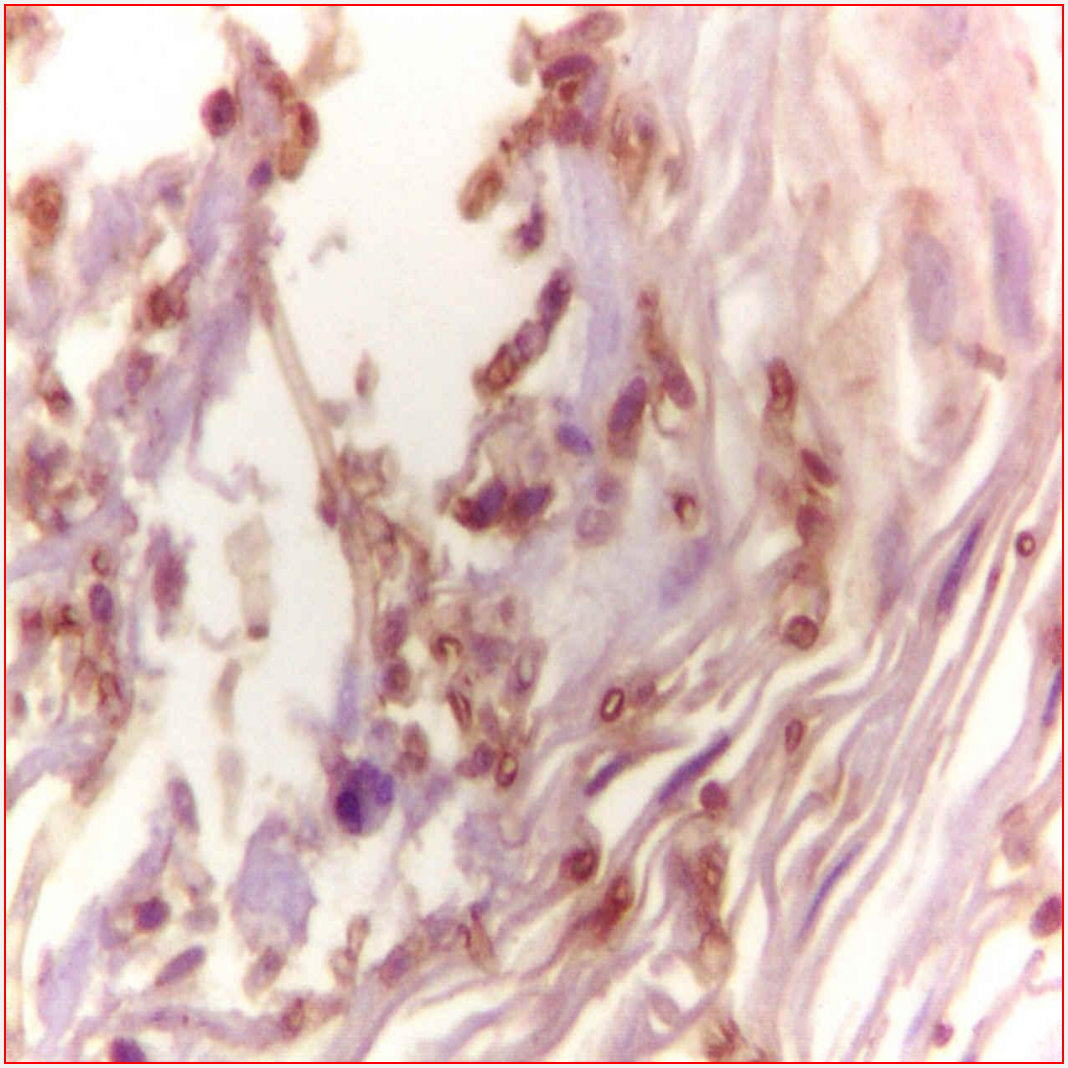

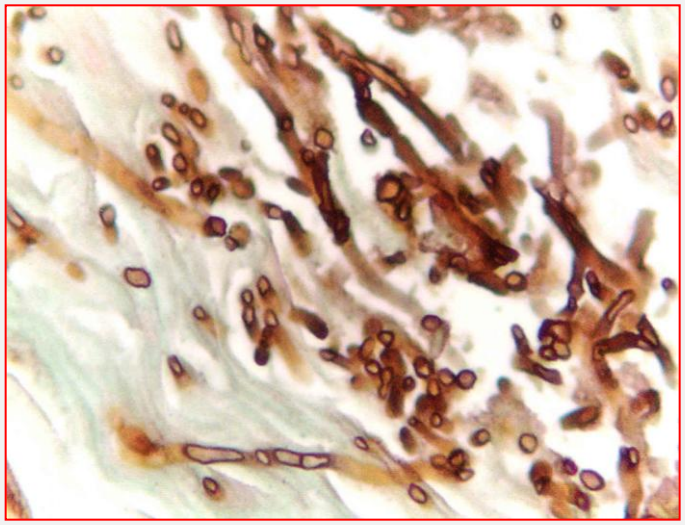

Histoplasma capsulatum

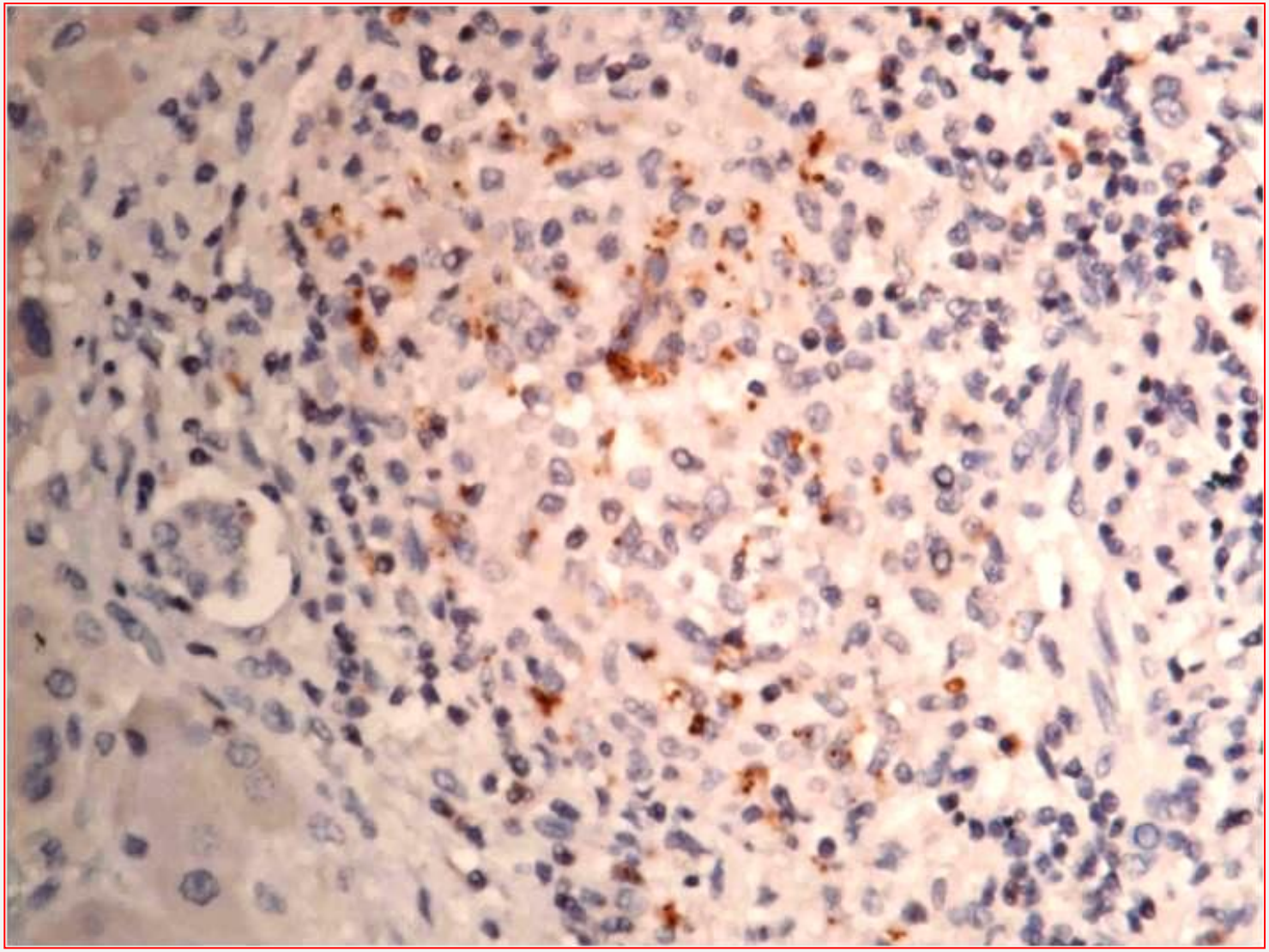

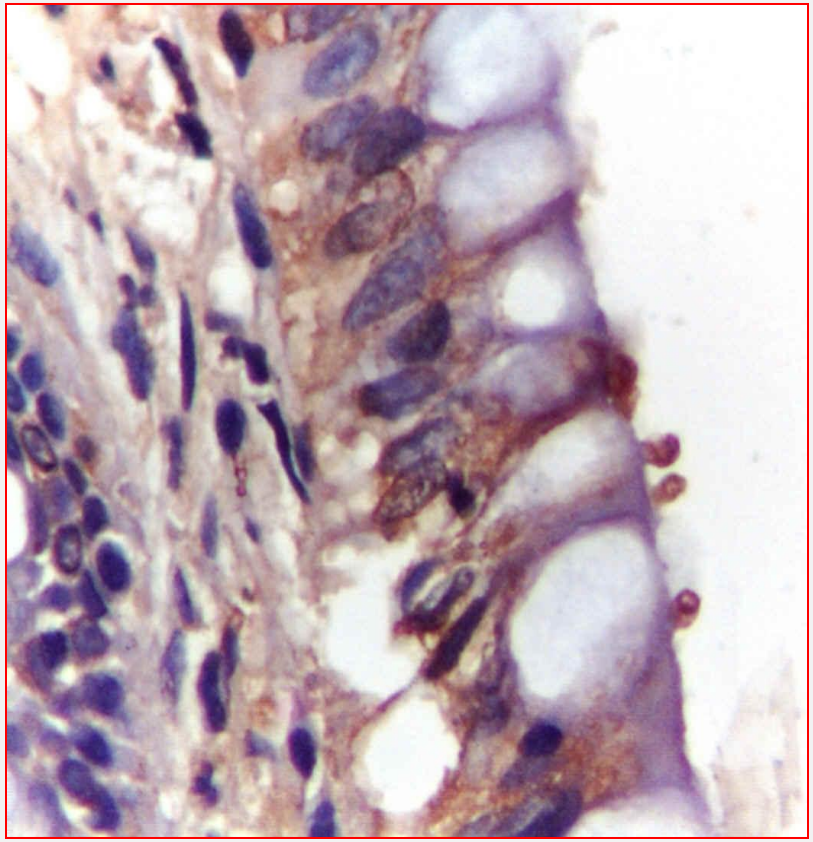

Criptosporidium sp

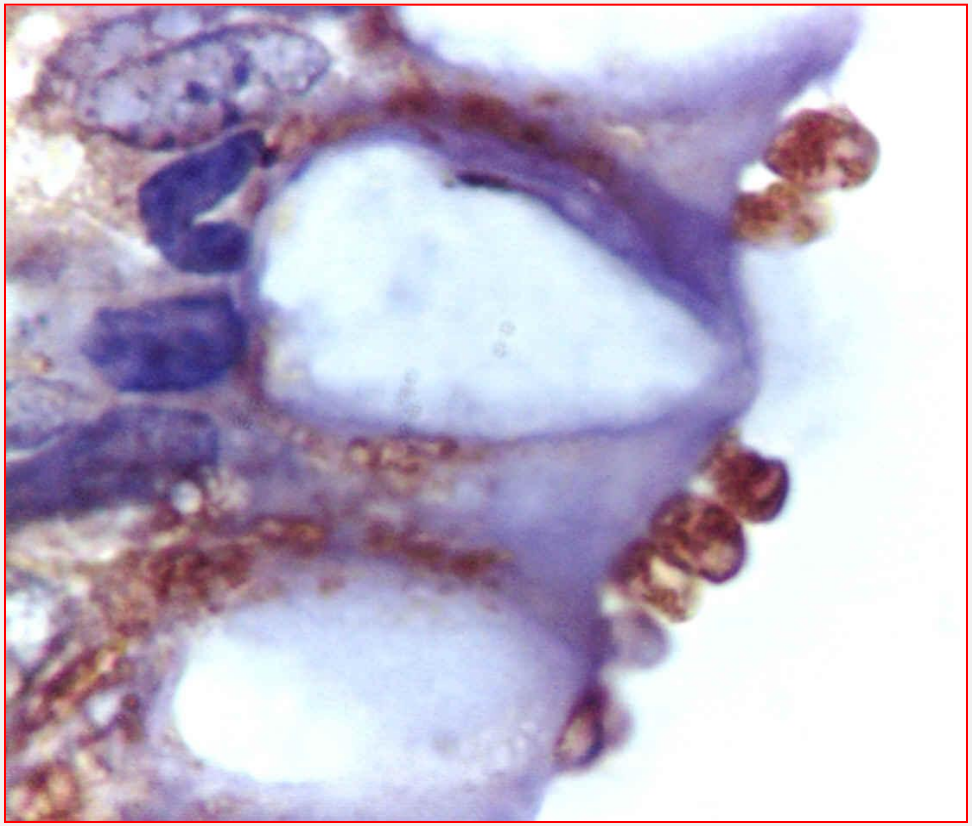

Trypanosoma cruzi

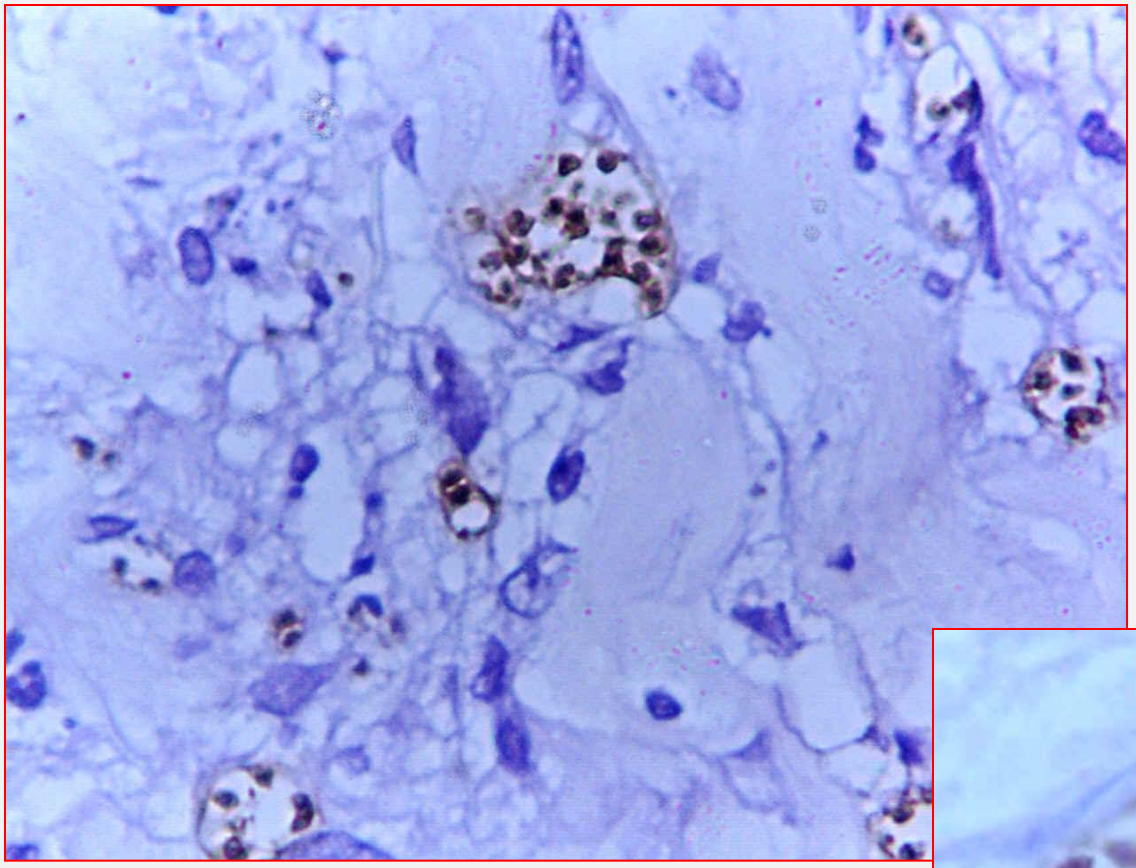

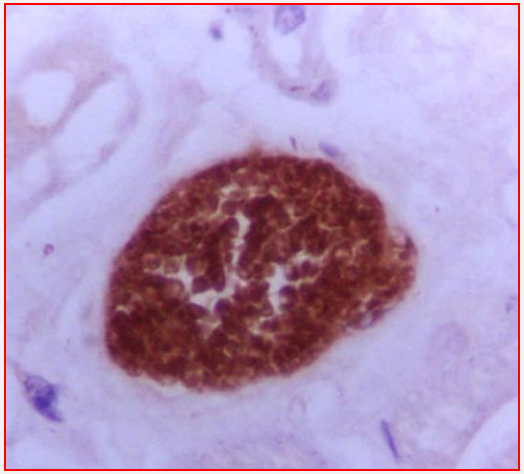

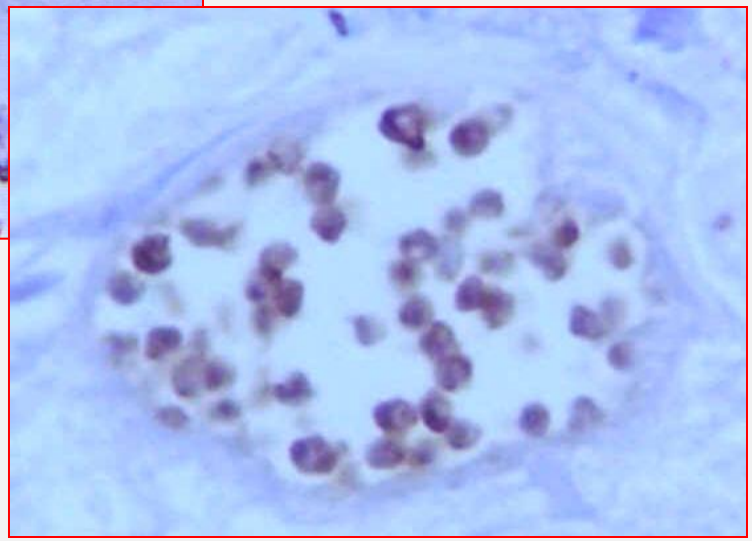

Leishmania

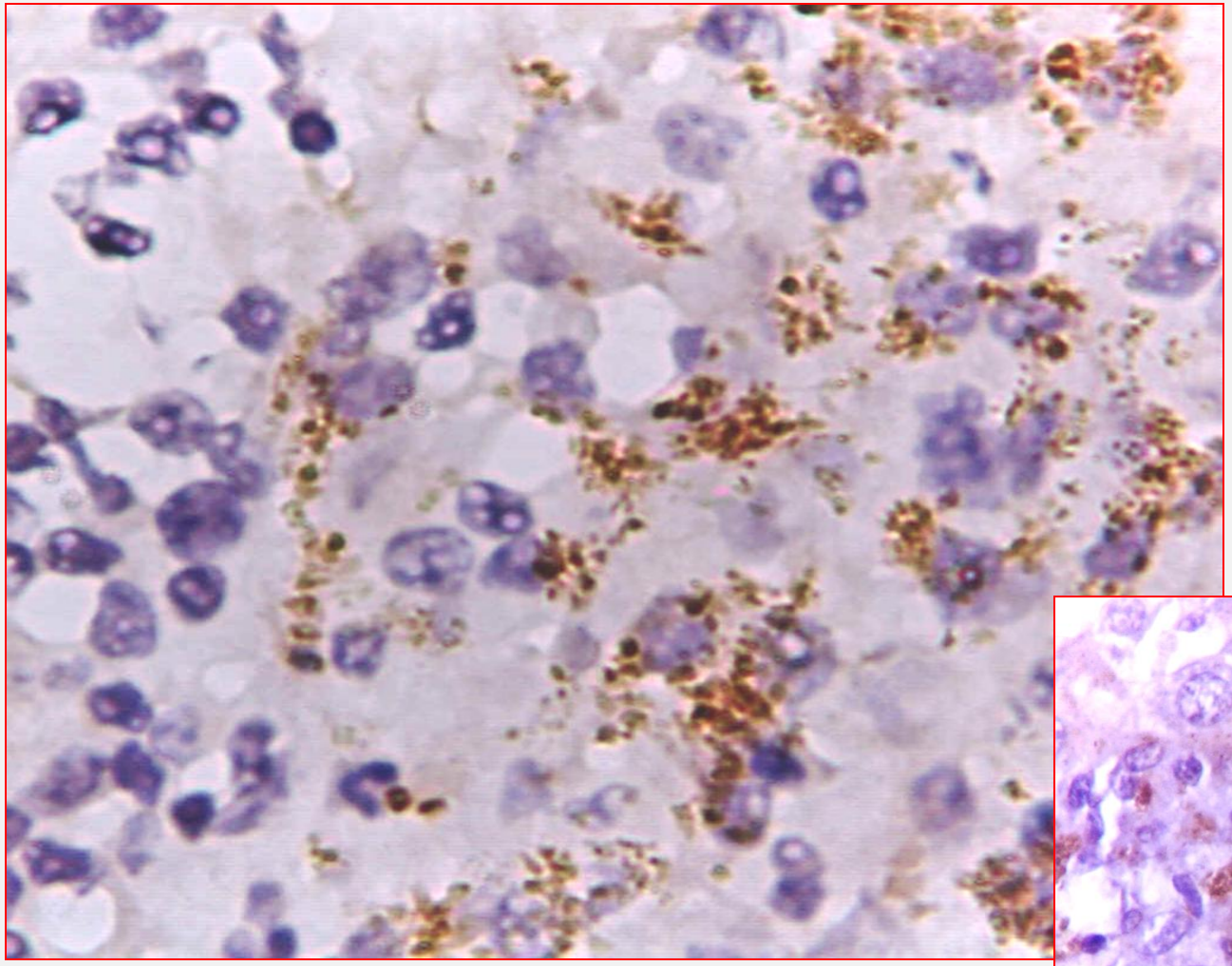

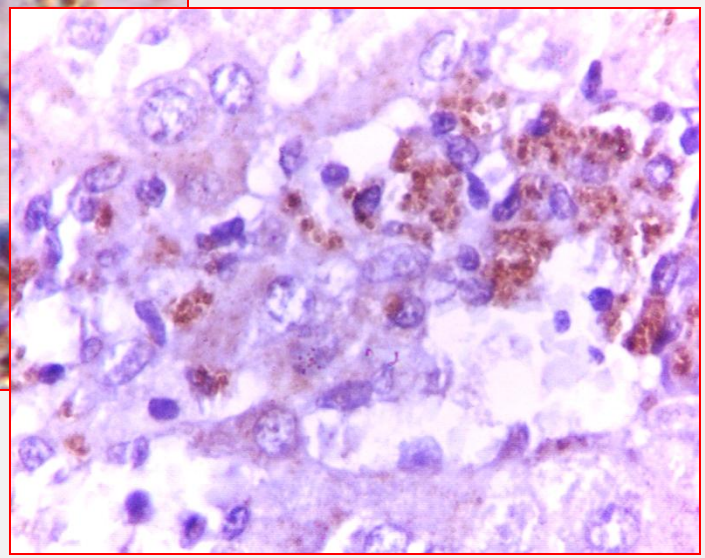

Shistosoma mansoni

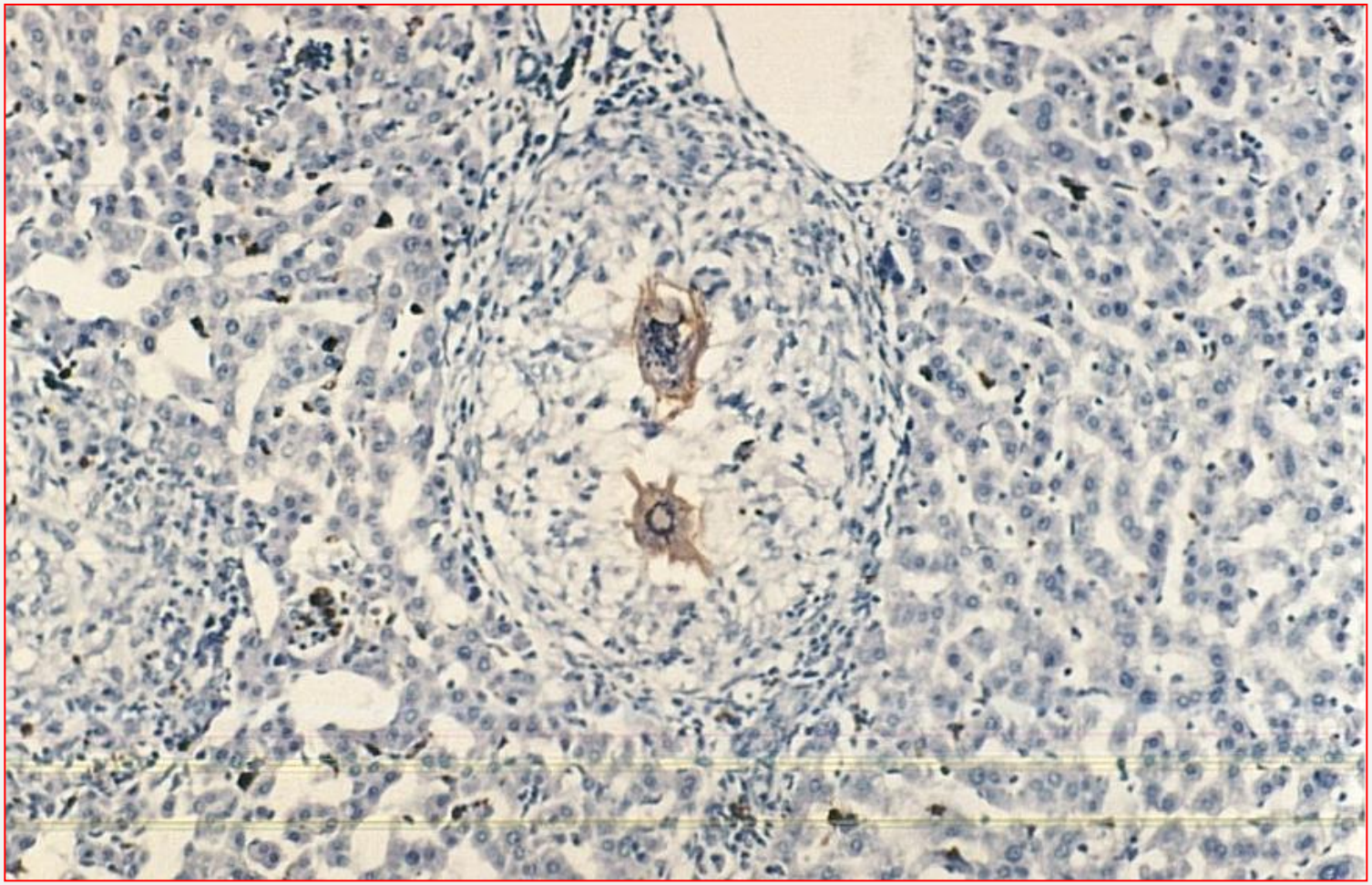

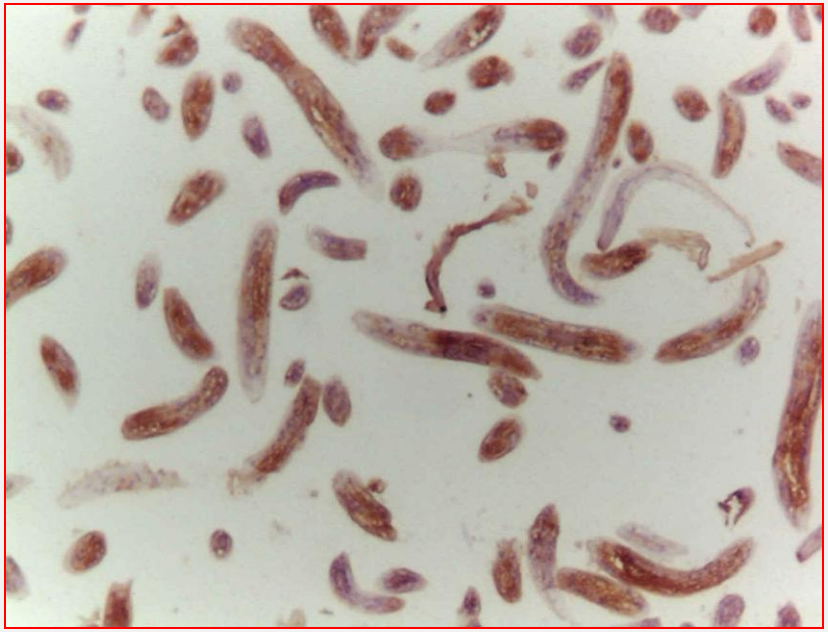

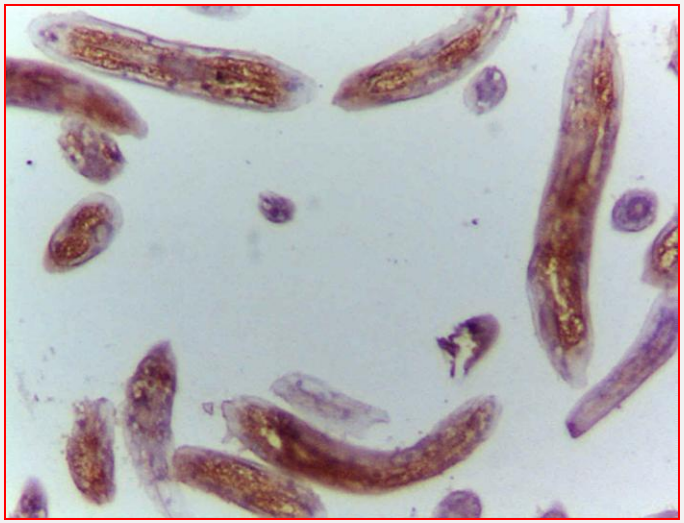

Toxocara

Dendrócitos Dérmicos FXIIIa+

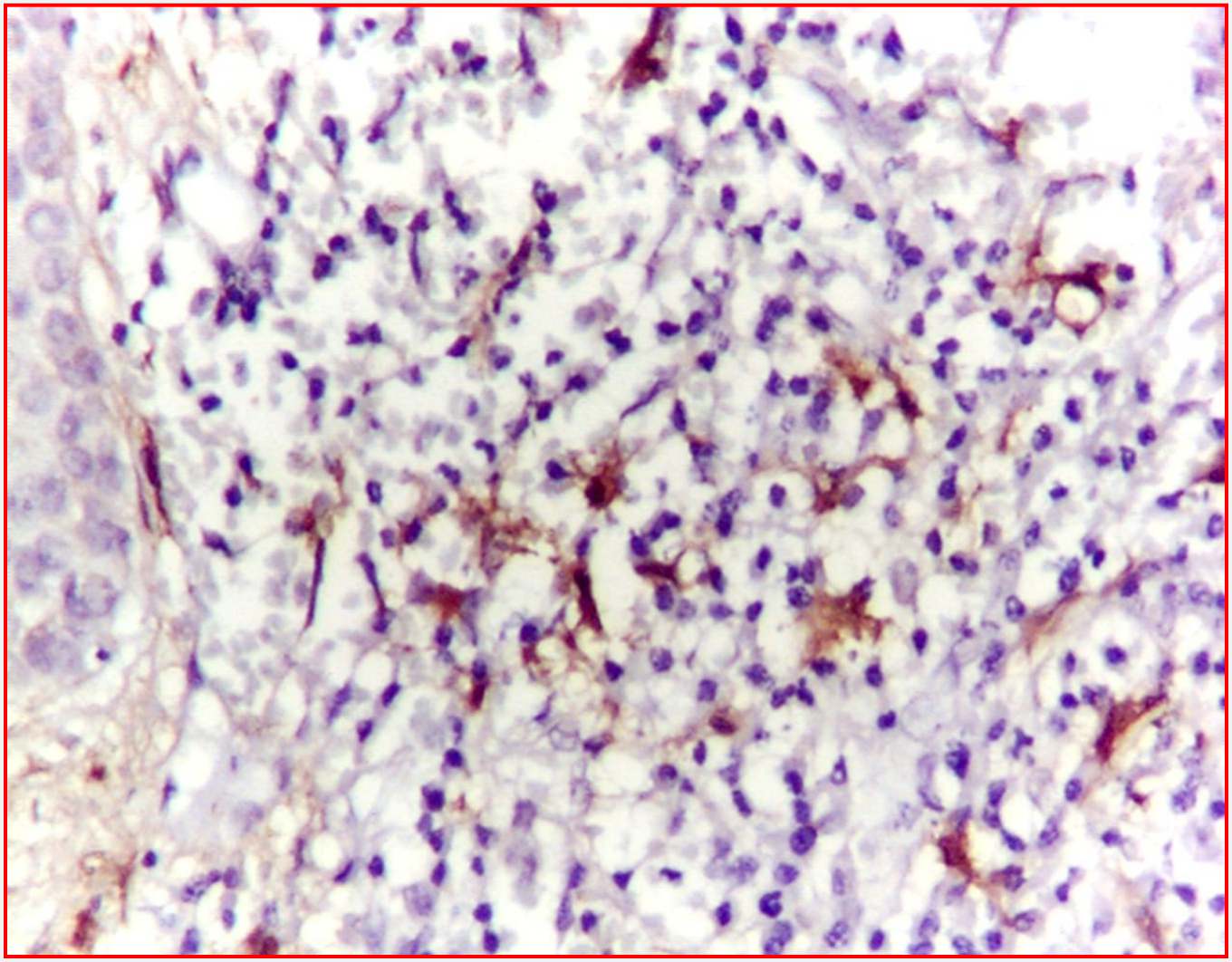

Células de Langerhans

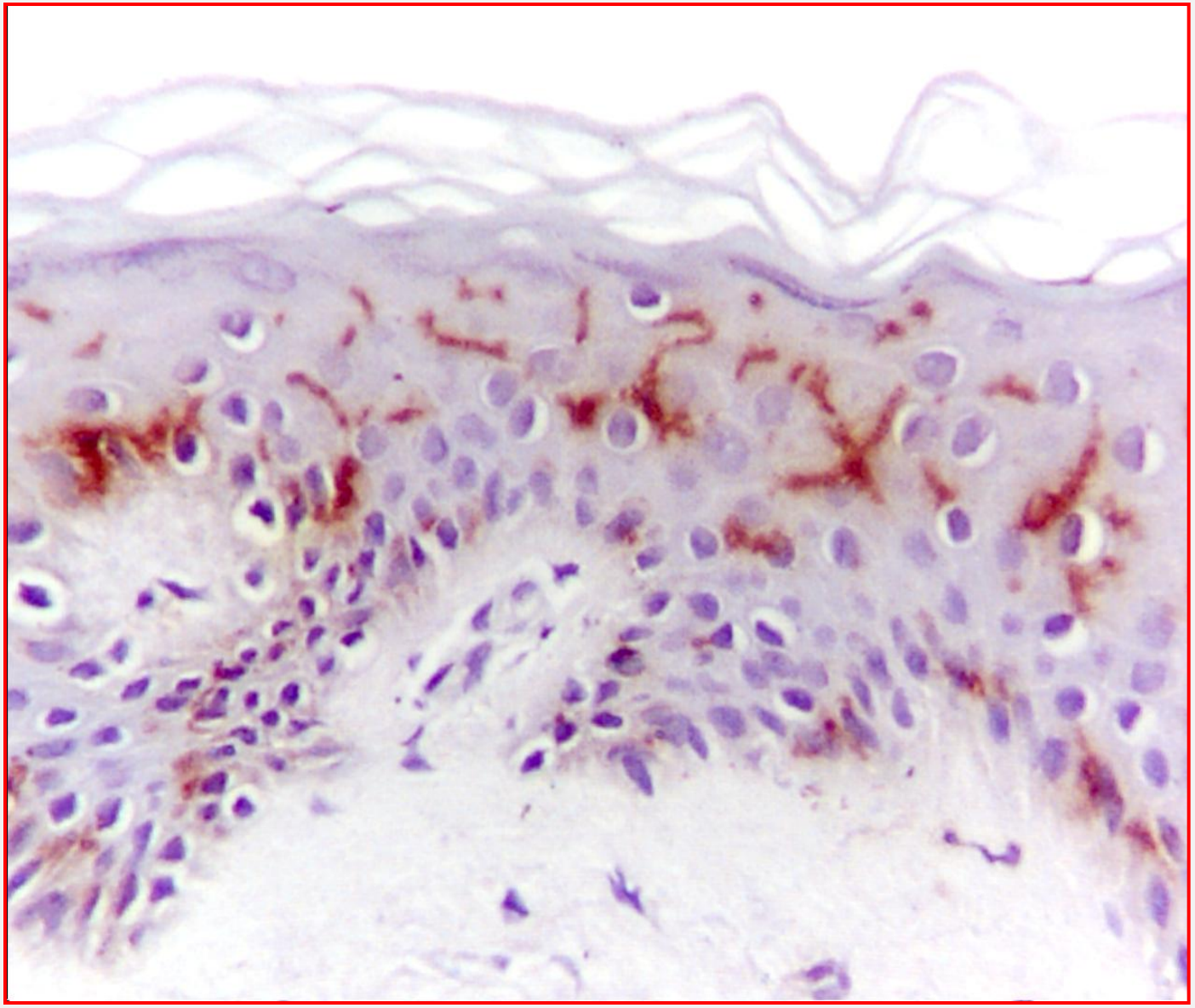

Langerina/CD207

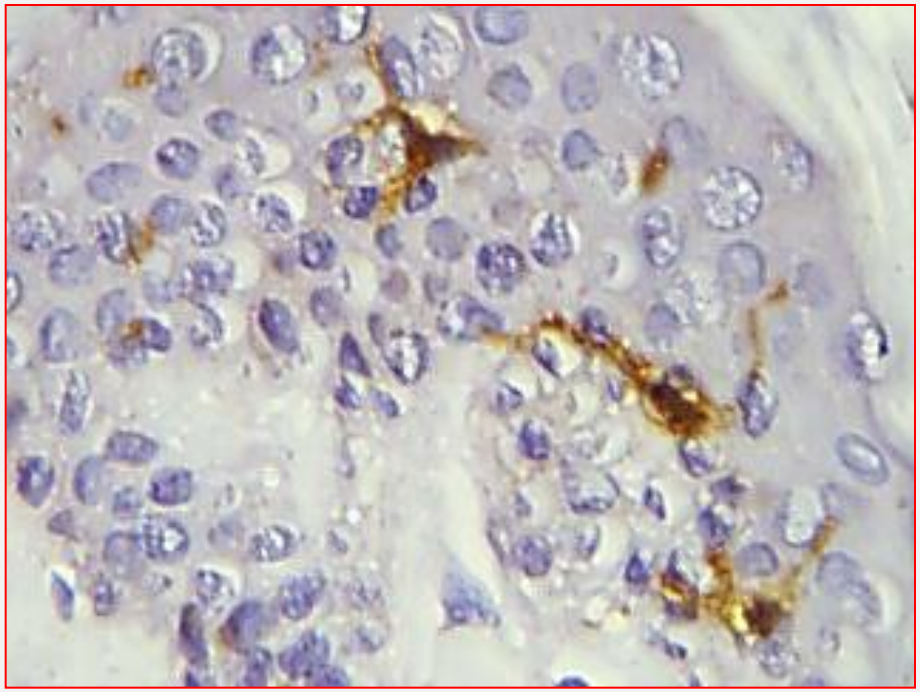

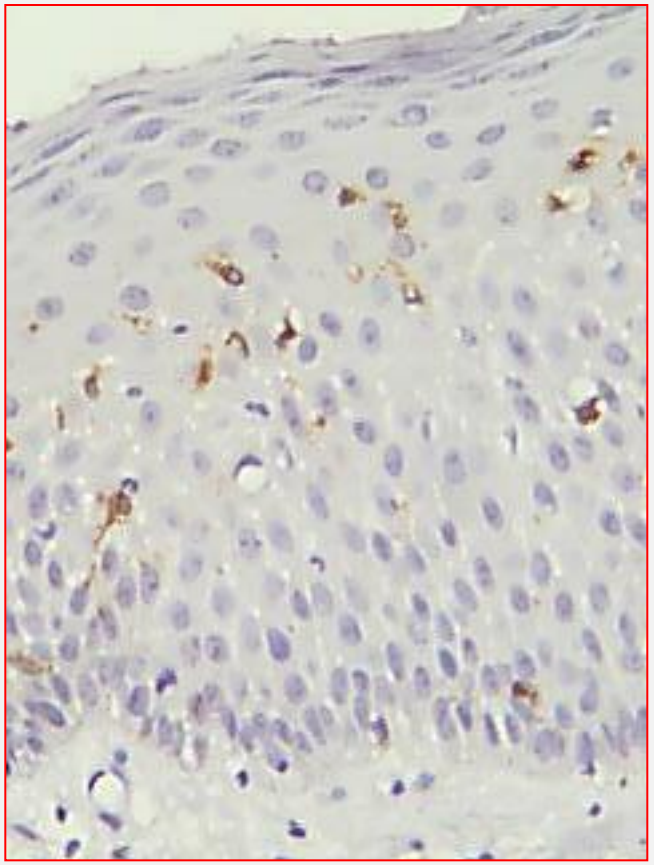

S100

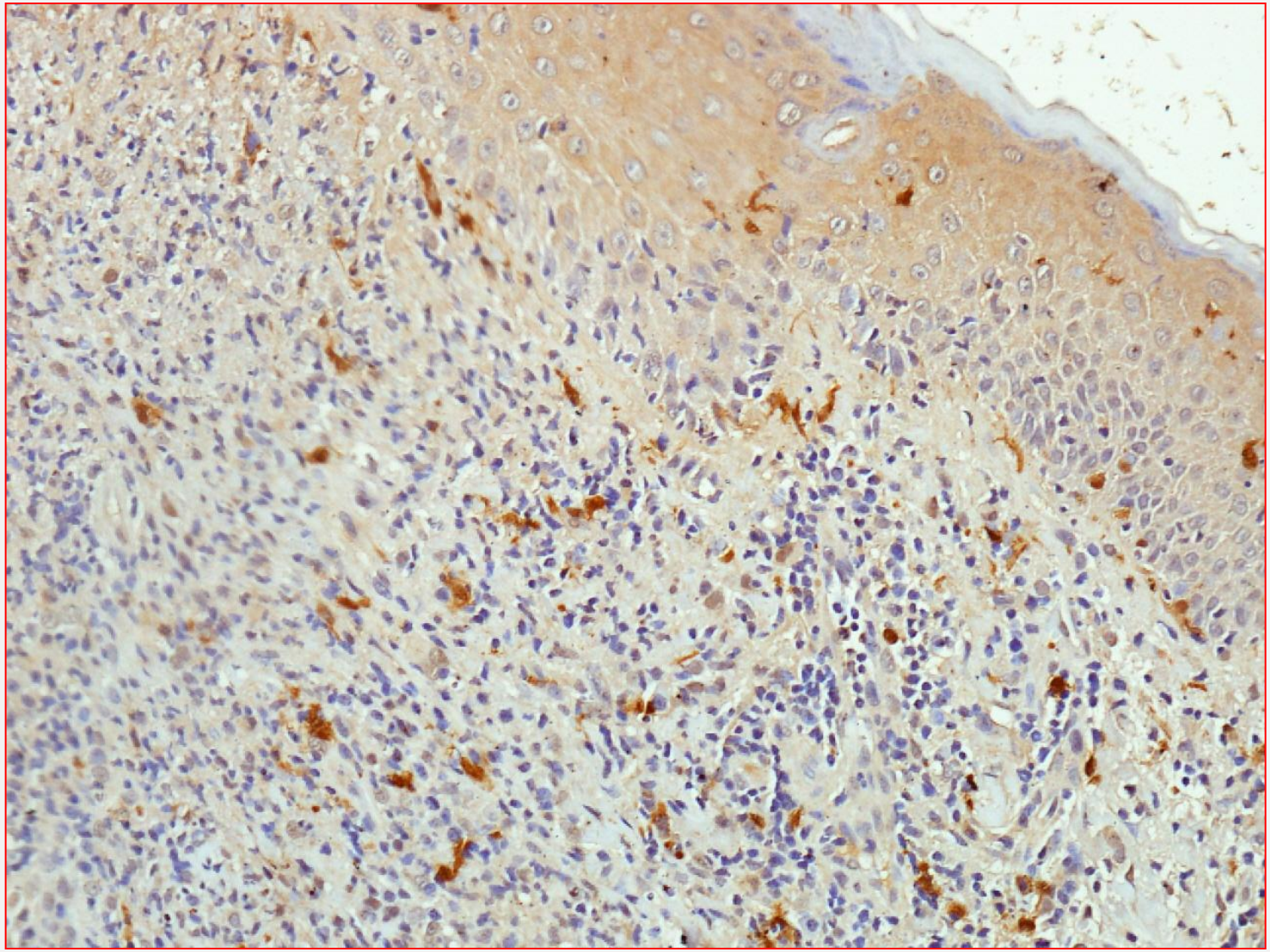

Macrófagos CD68+

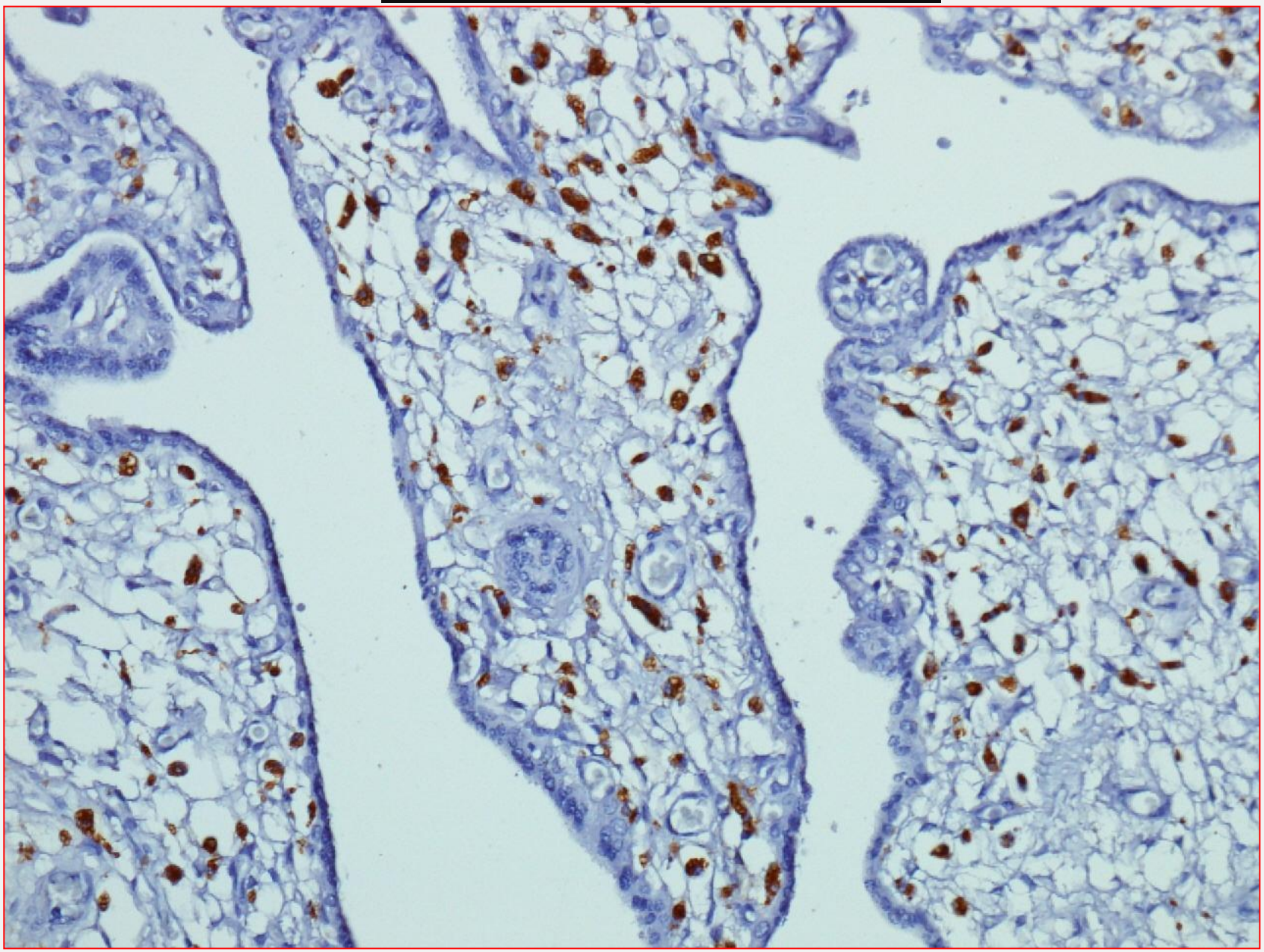

Linfócitos T CD4+ (OPD4)

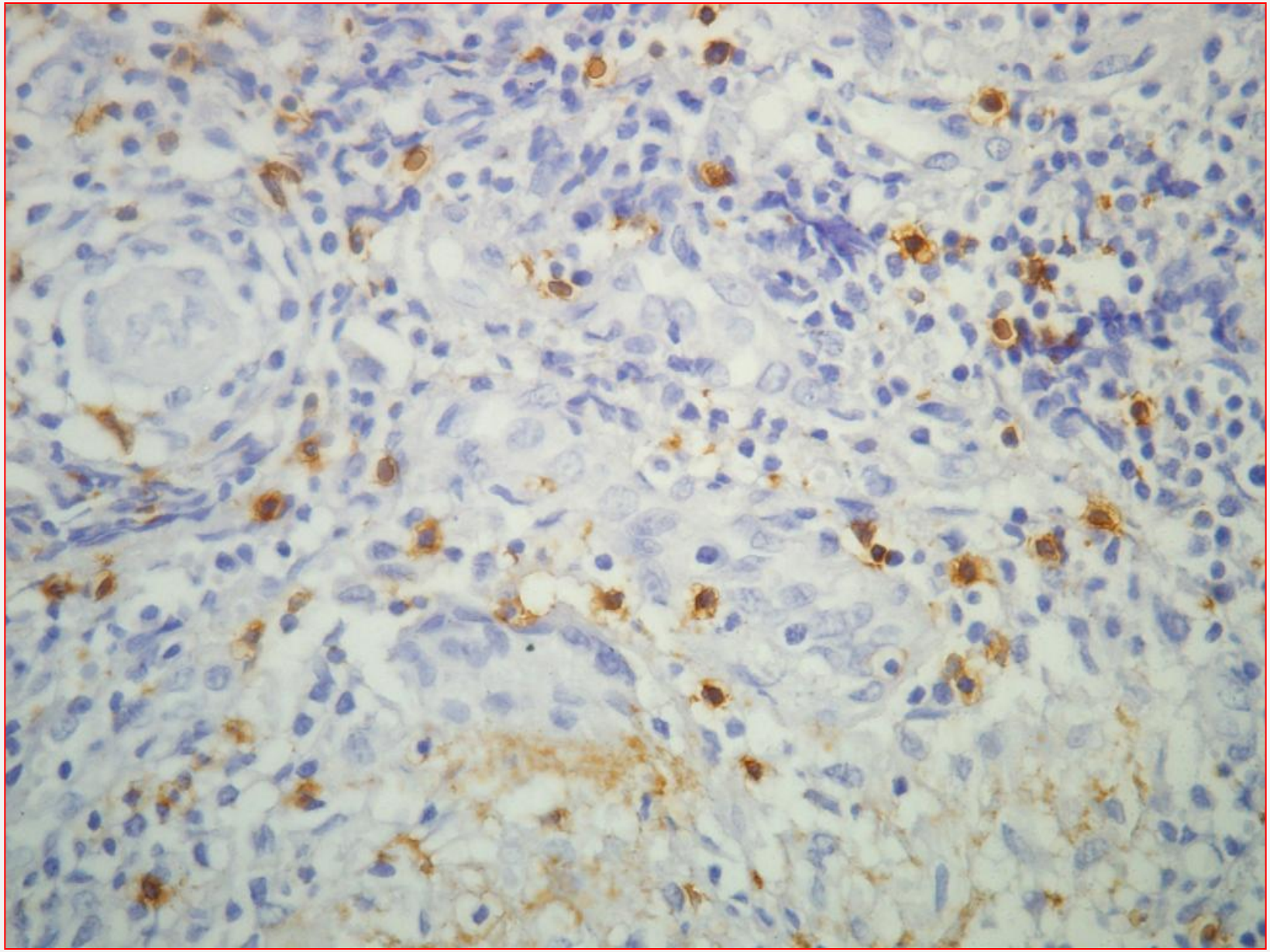

Resposta Th1, Th2, Treg, Th17

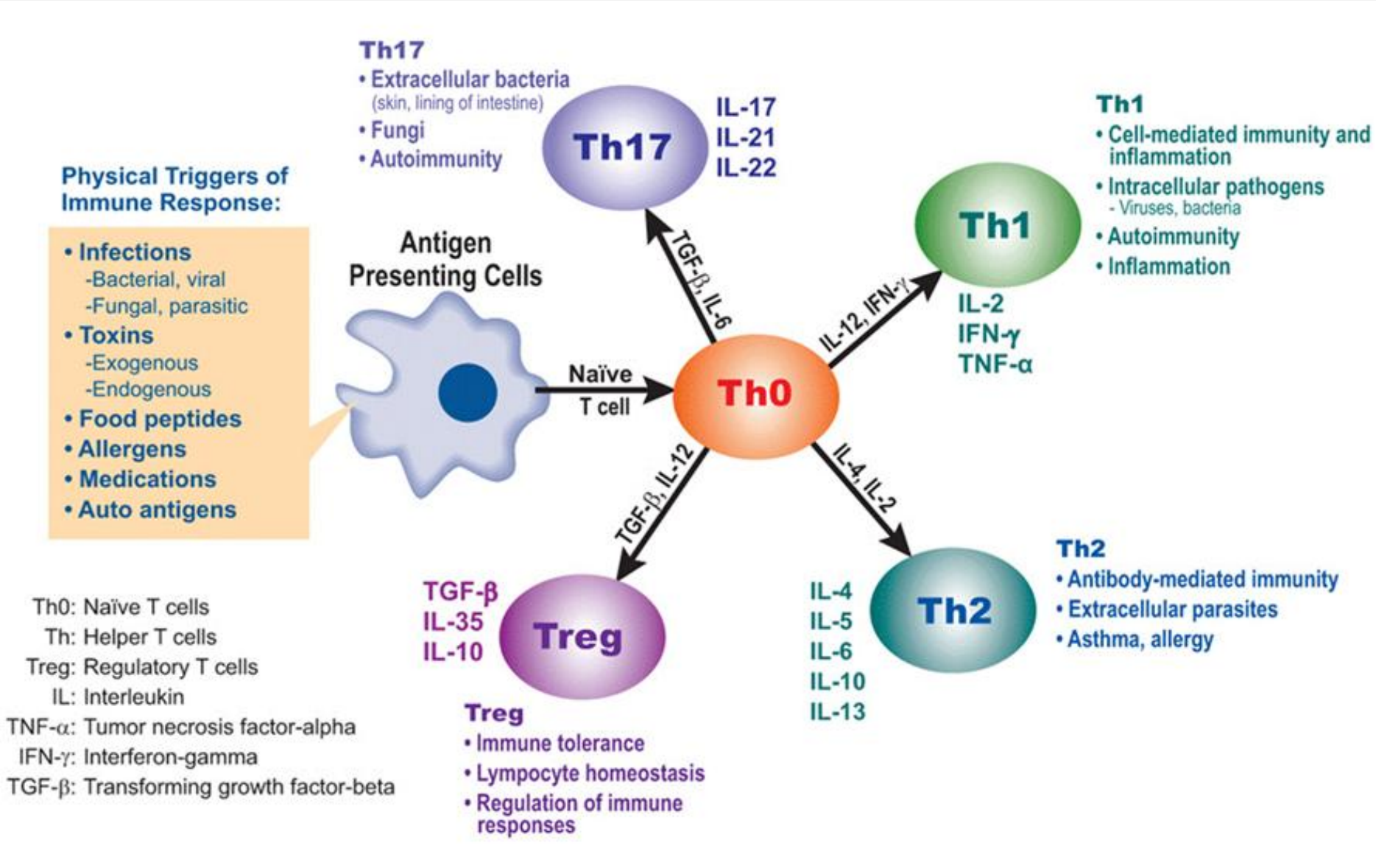

Linfócitos T reguladores Foxp3+

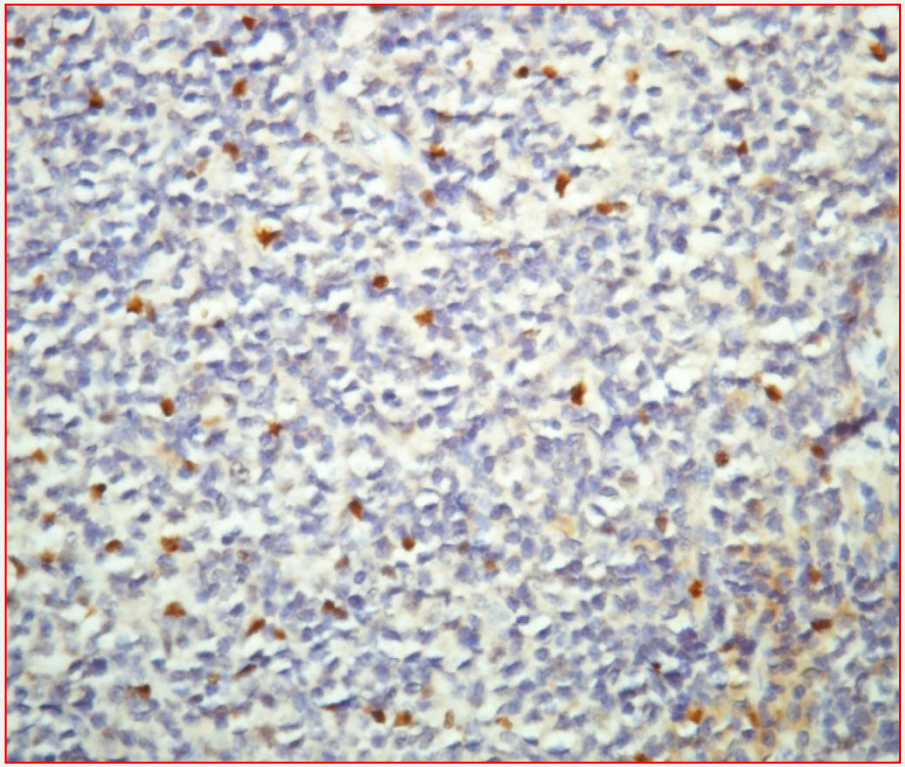

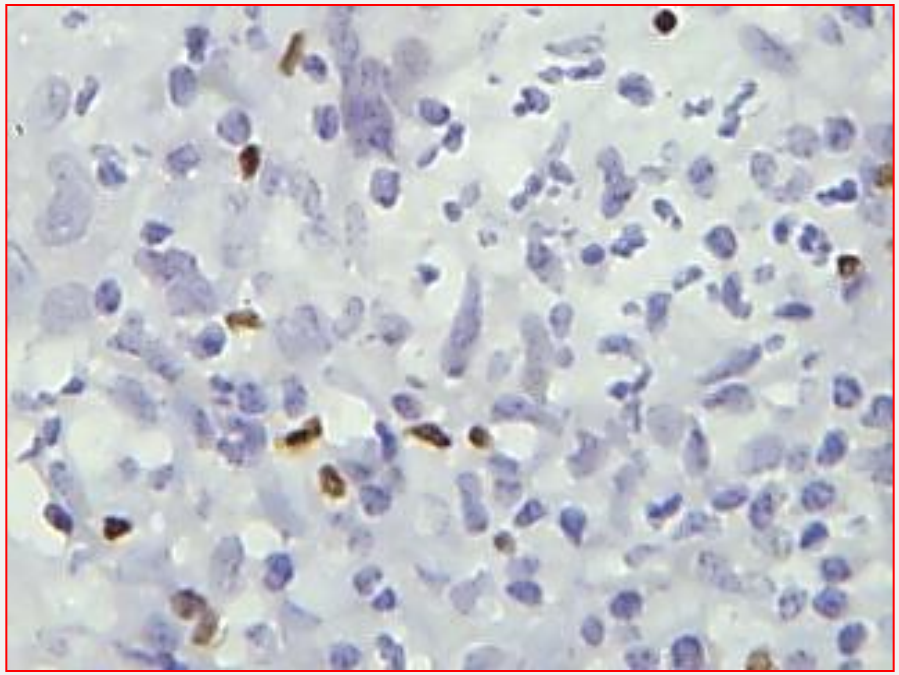

Células com expressão de TNF-α

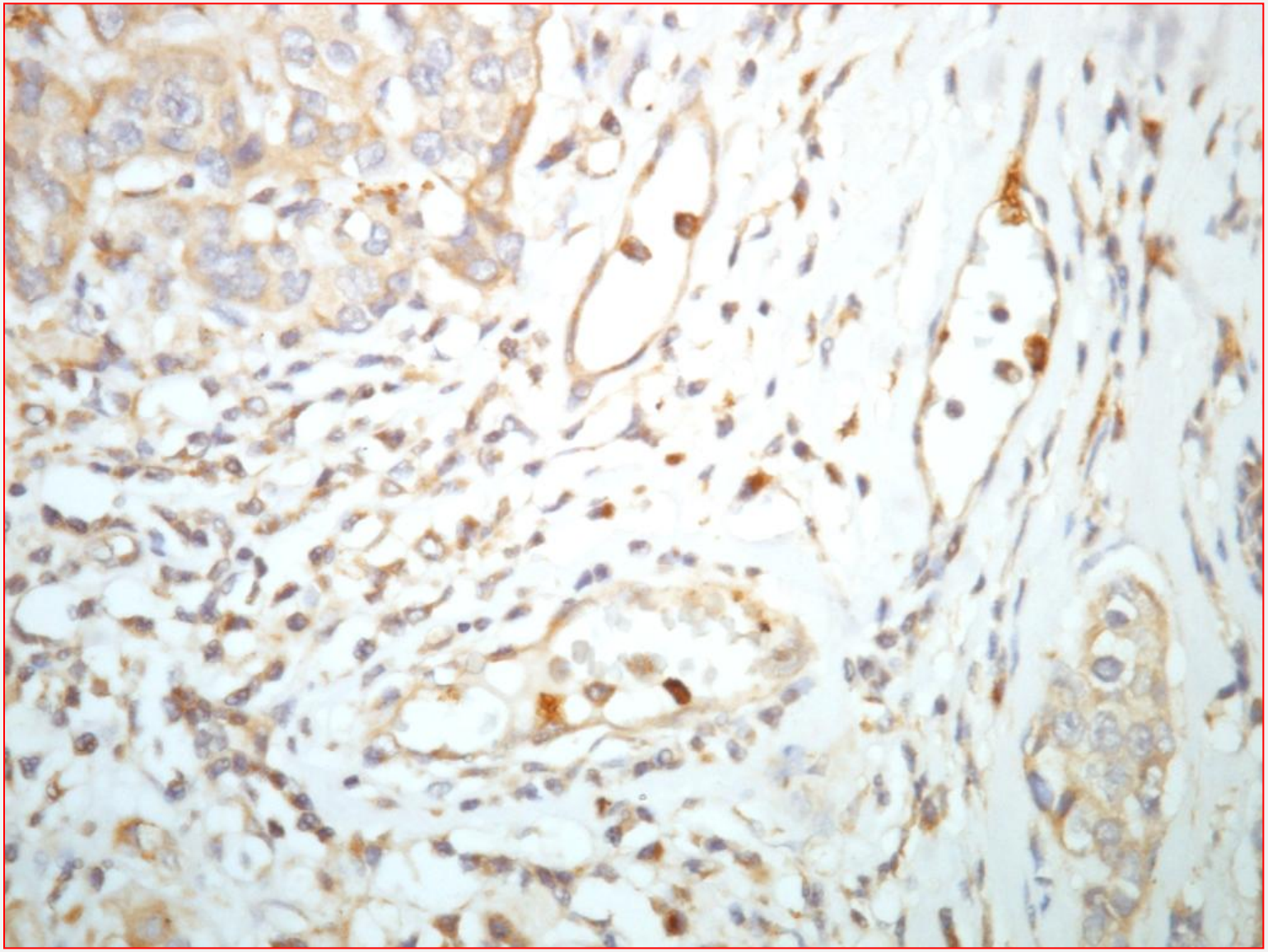

Células com expressão de IFN-γ

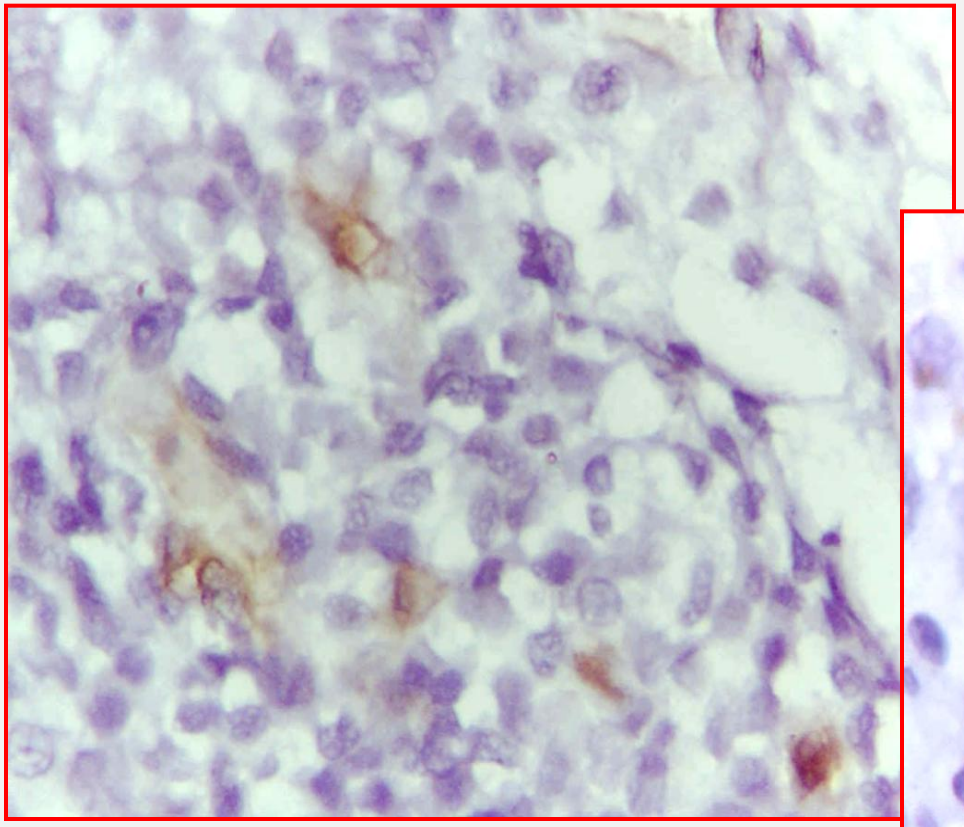

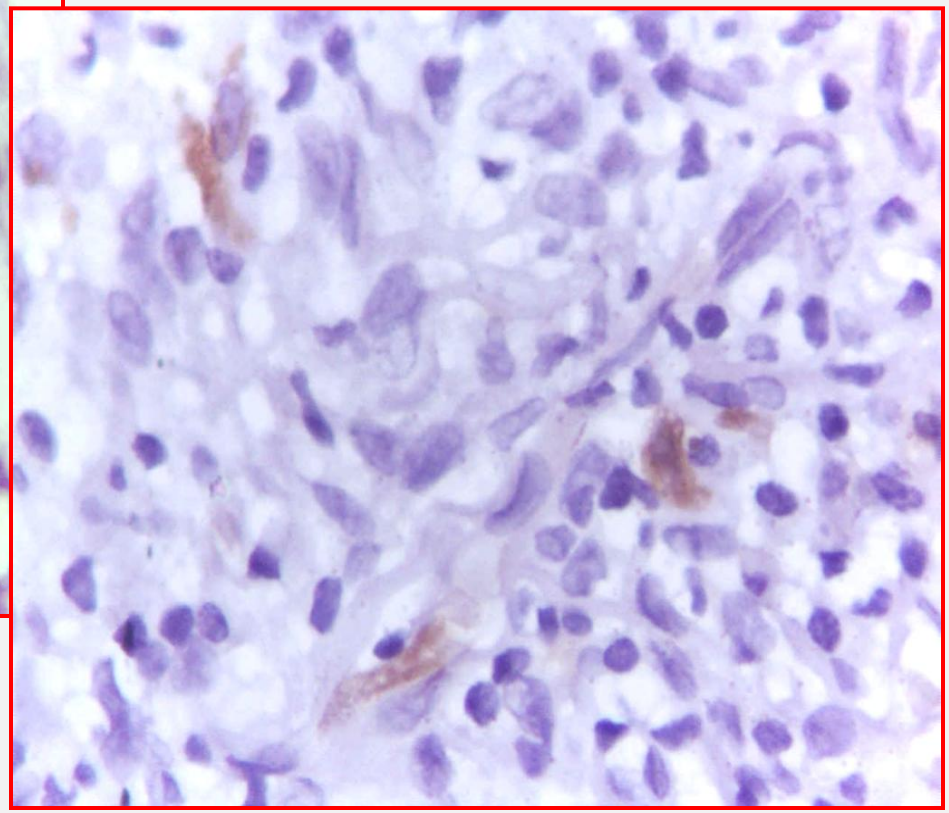

Expressão de TGF beta

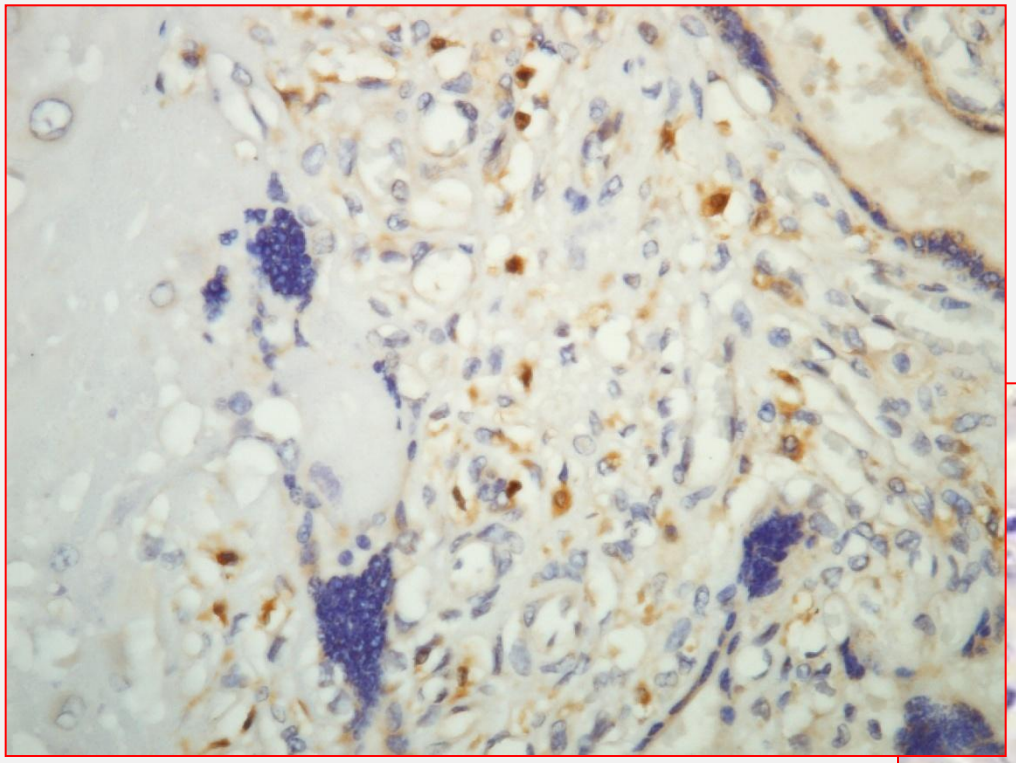

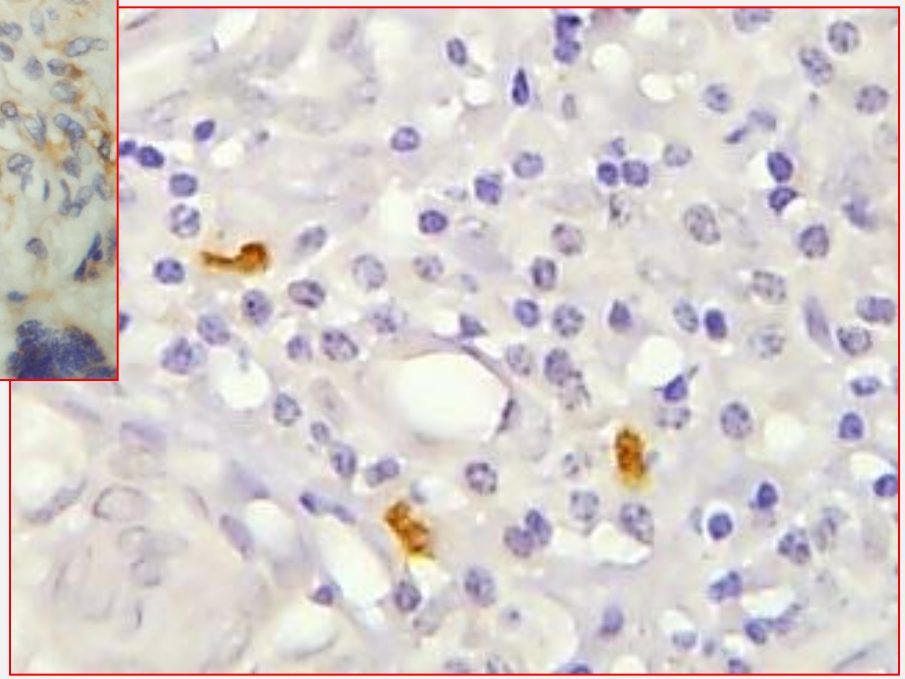

Células com expressão de IL1

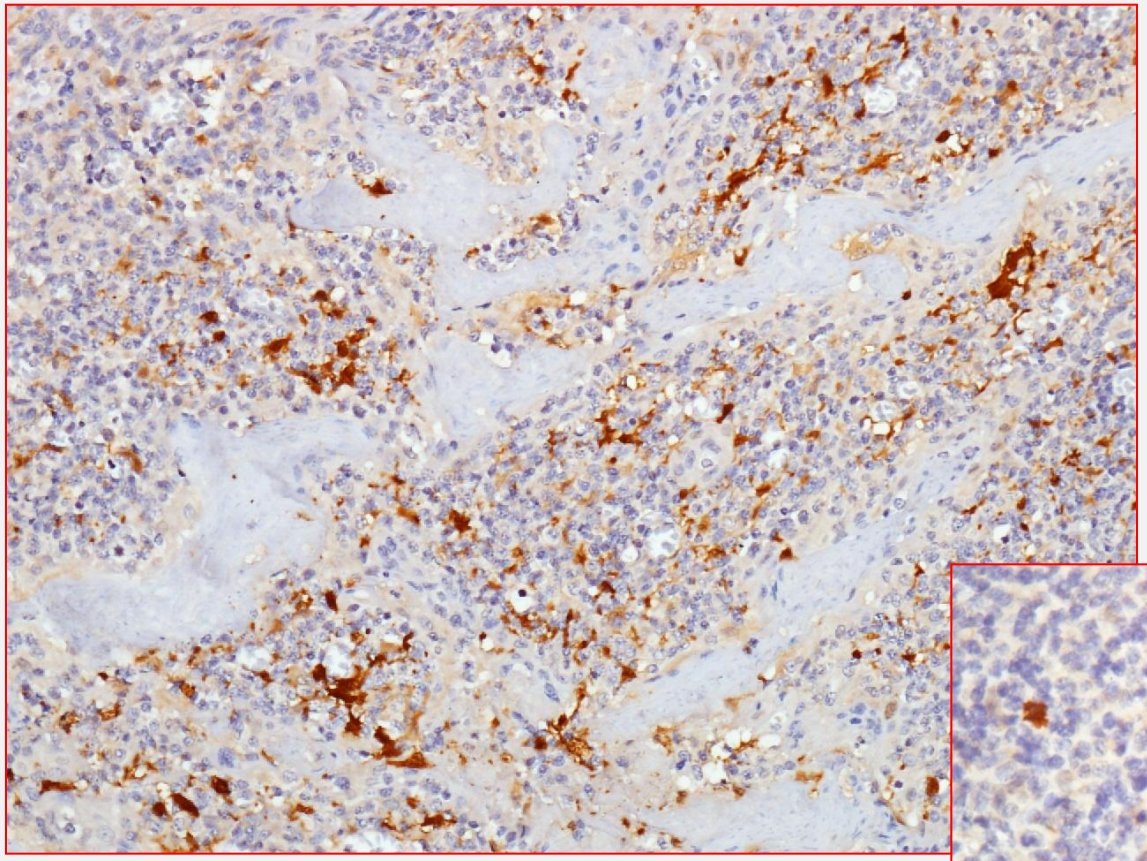

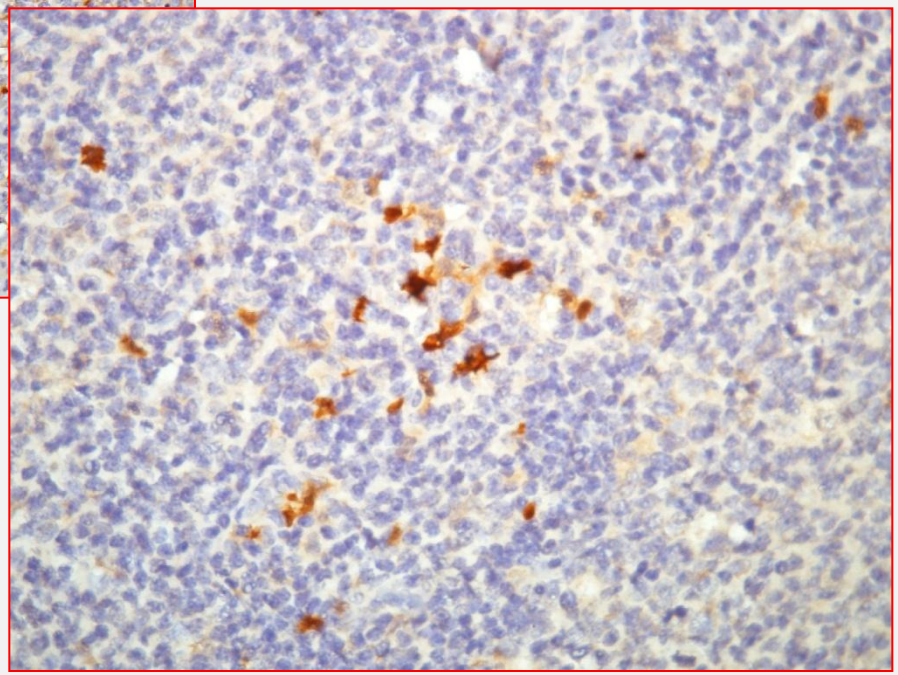

Células com expressão de IL4

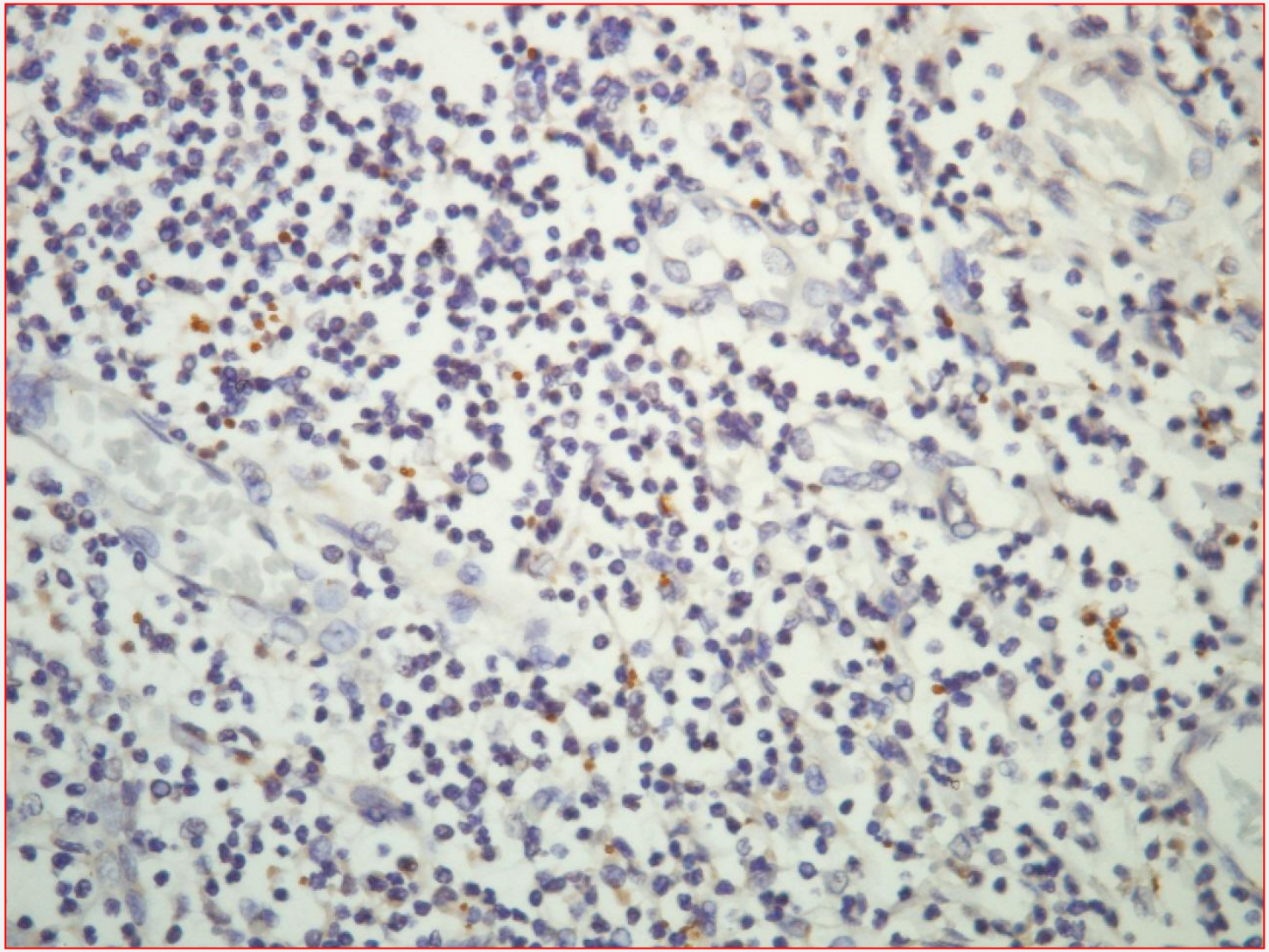

Células com expressão de IL-5

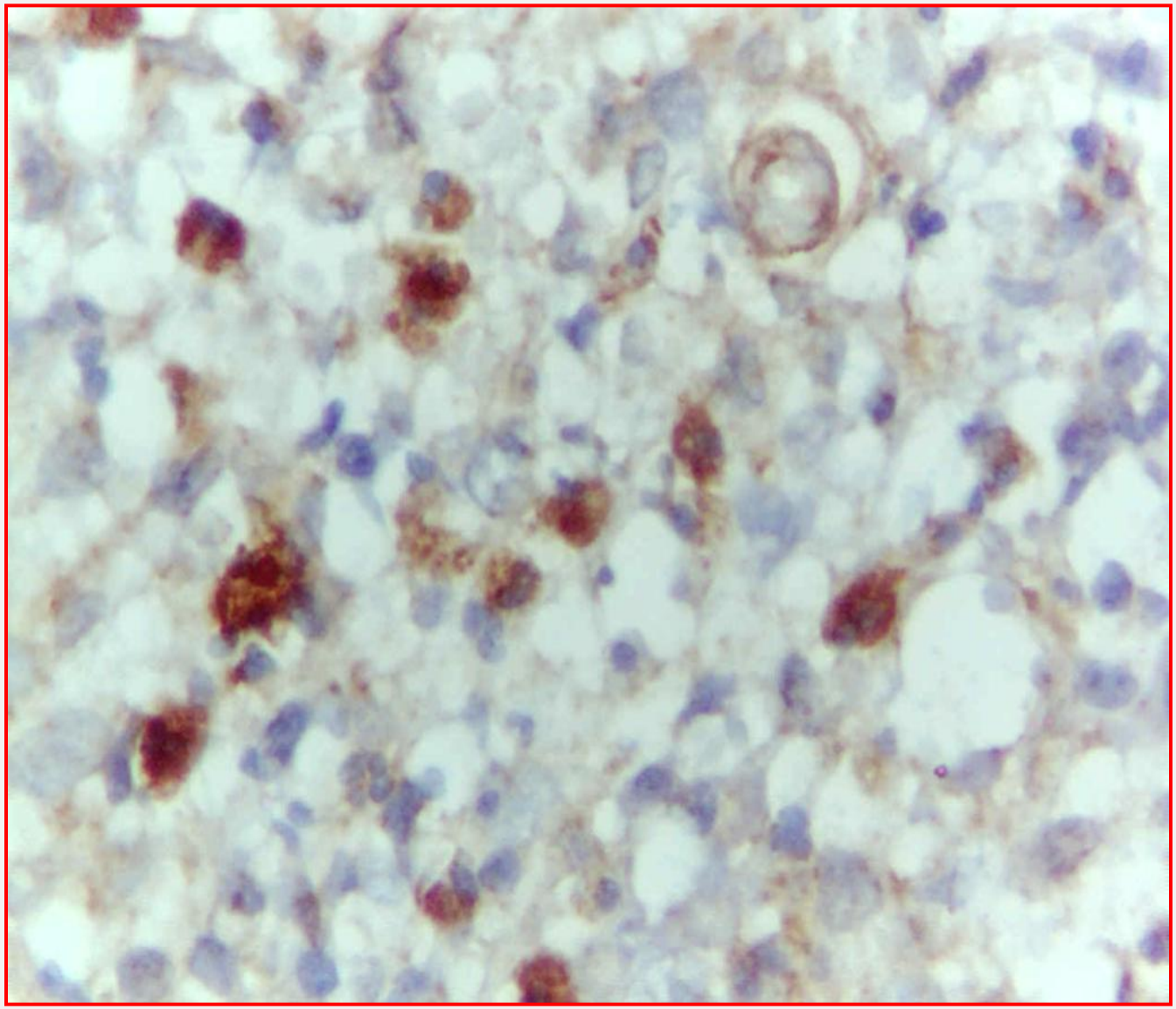

Células com expressão de IL-10

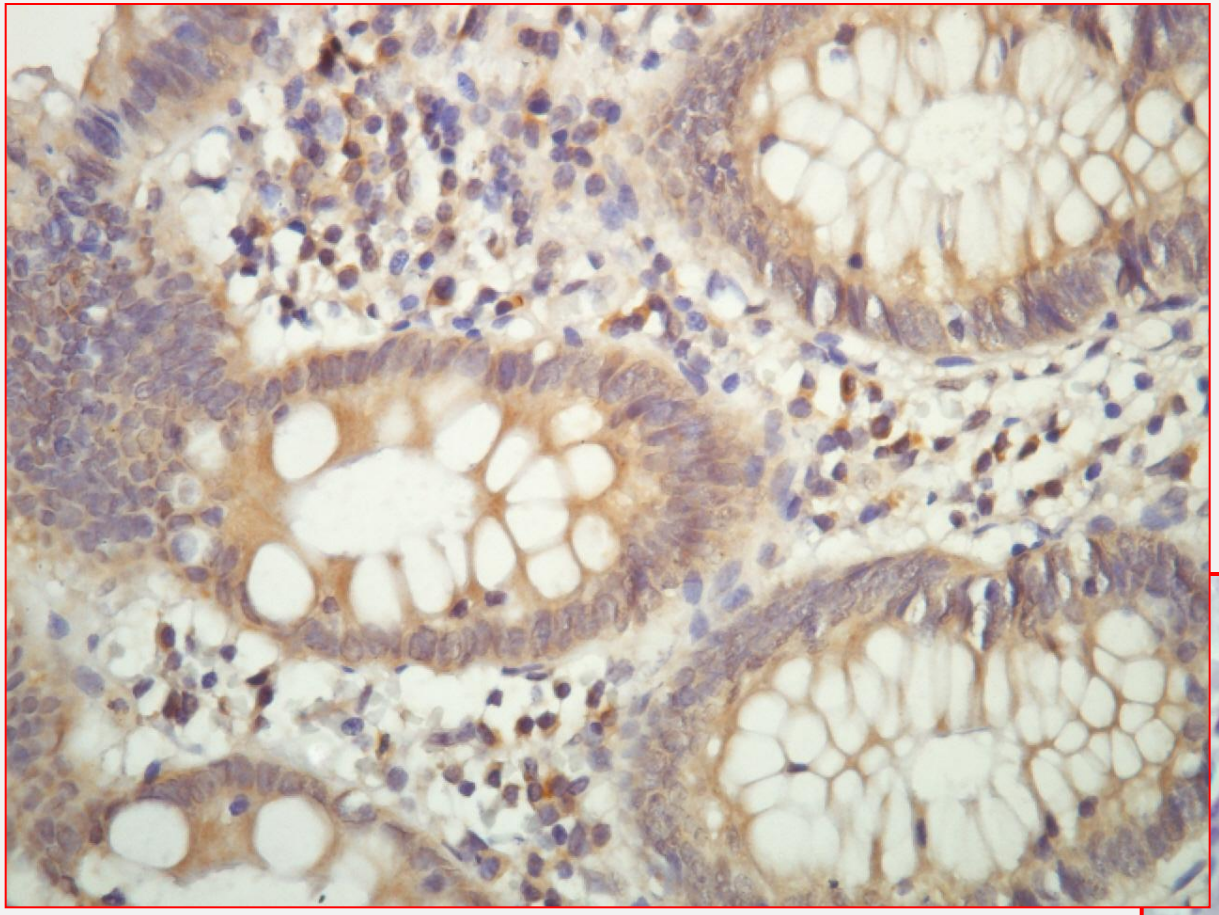

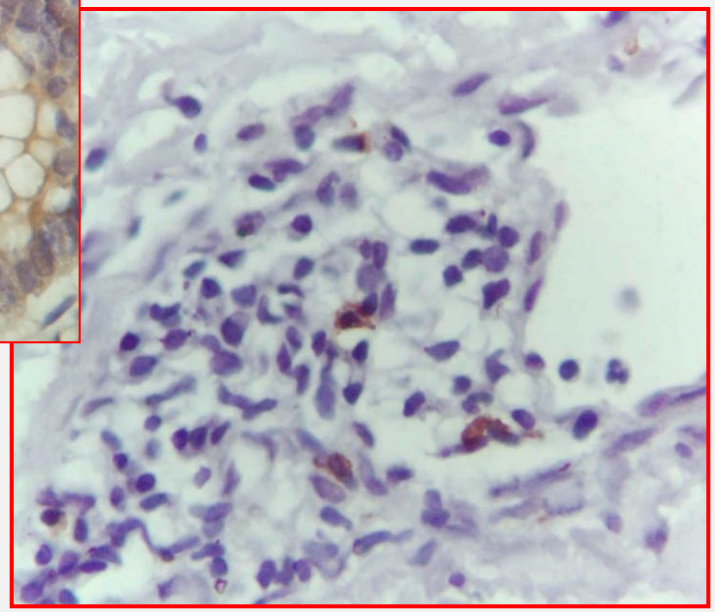

Células com expressão de IL17

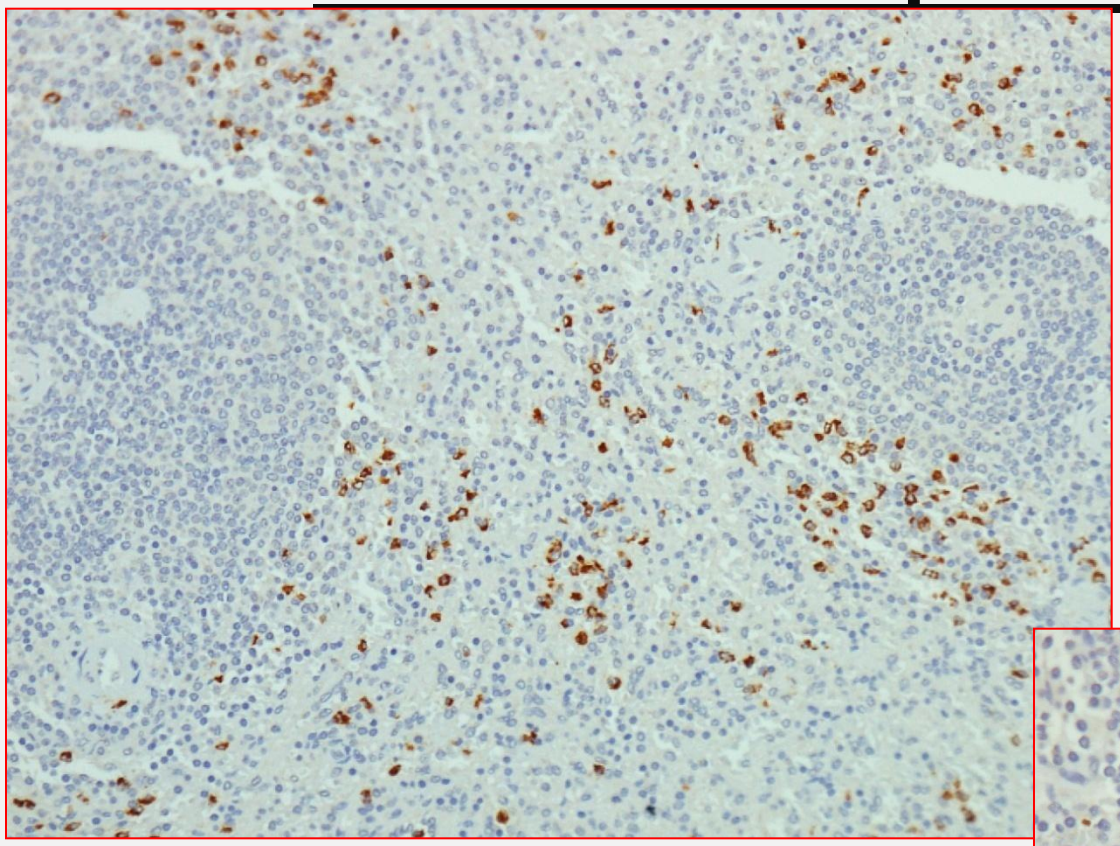

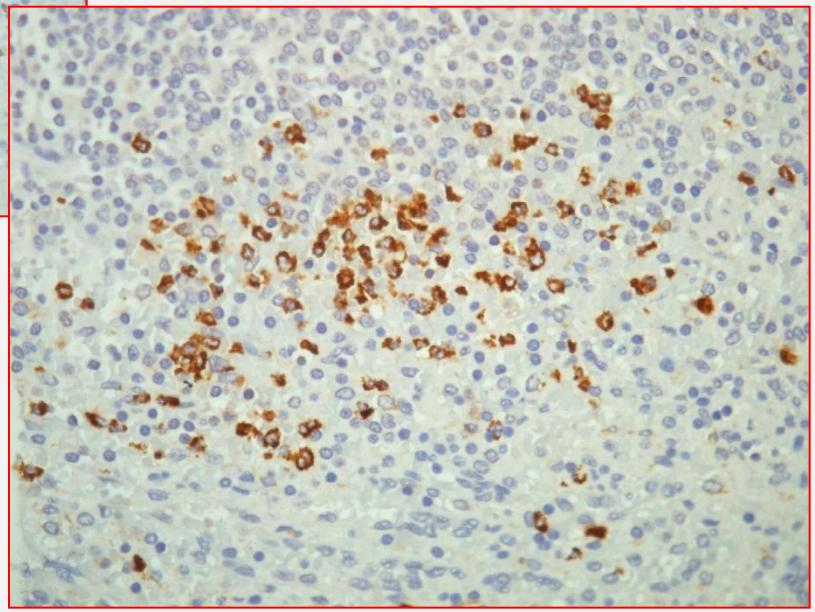

Linfócitos T CD8+

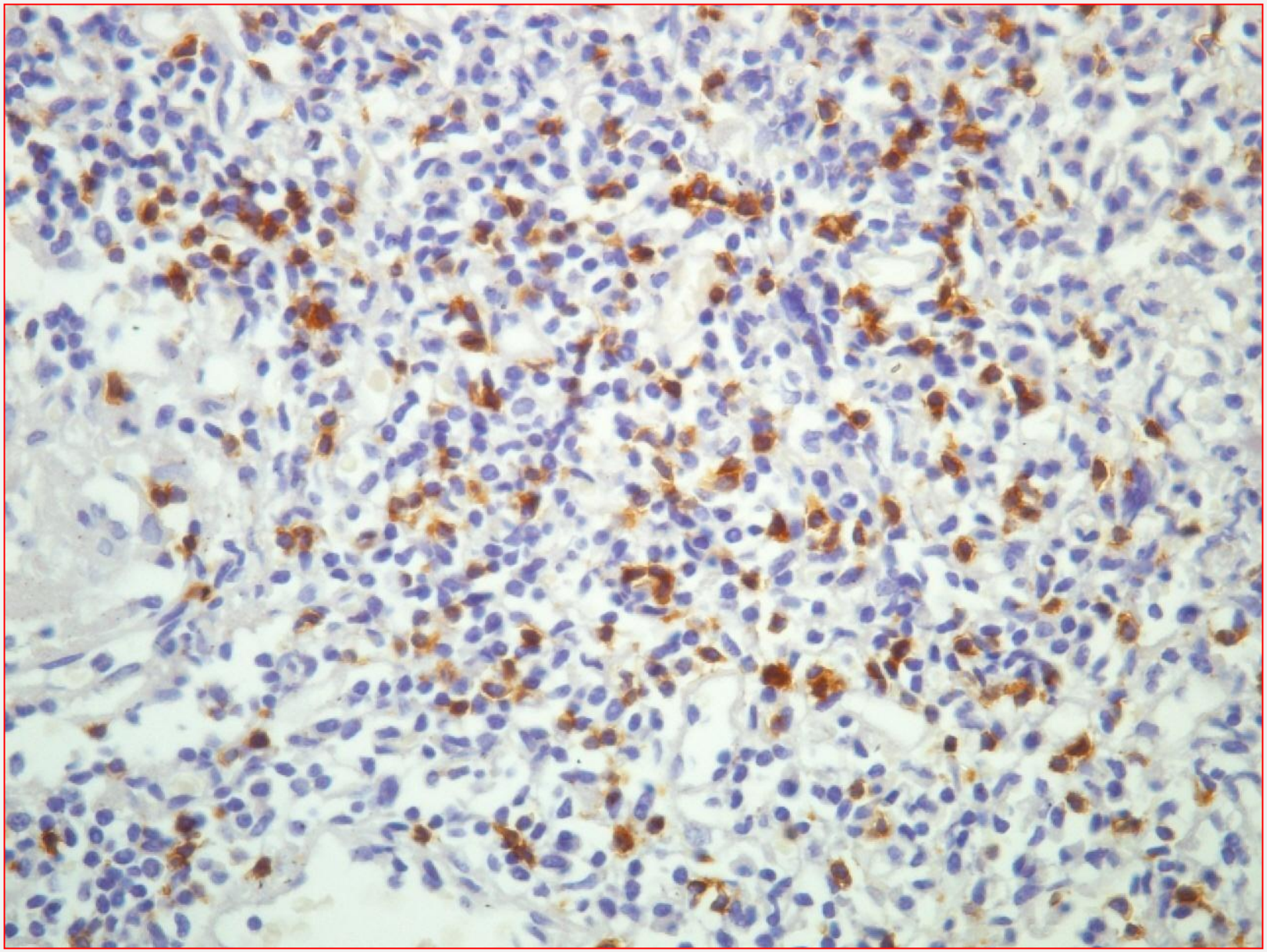

Granzima B

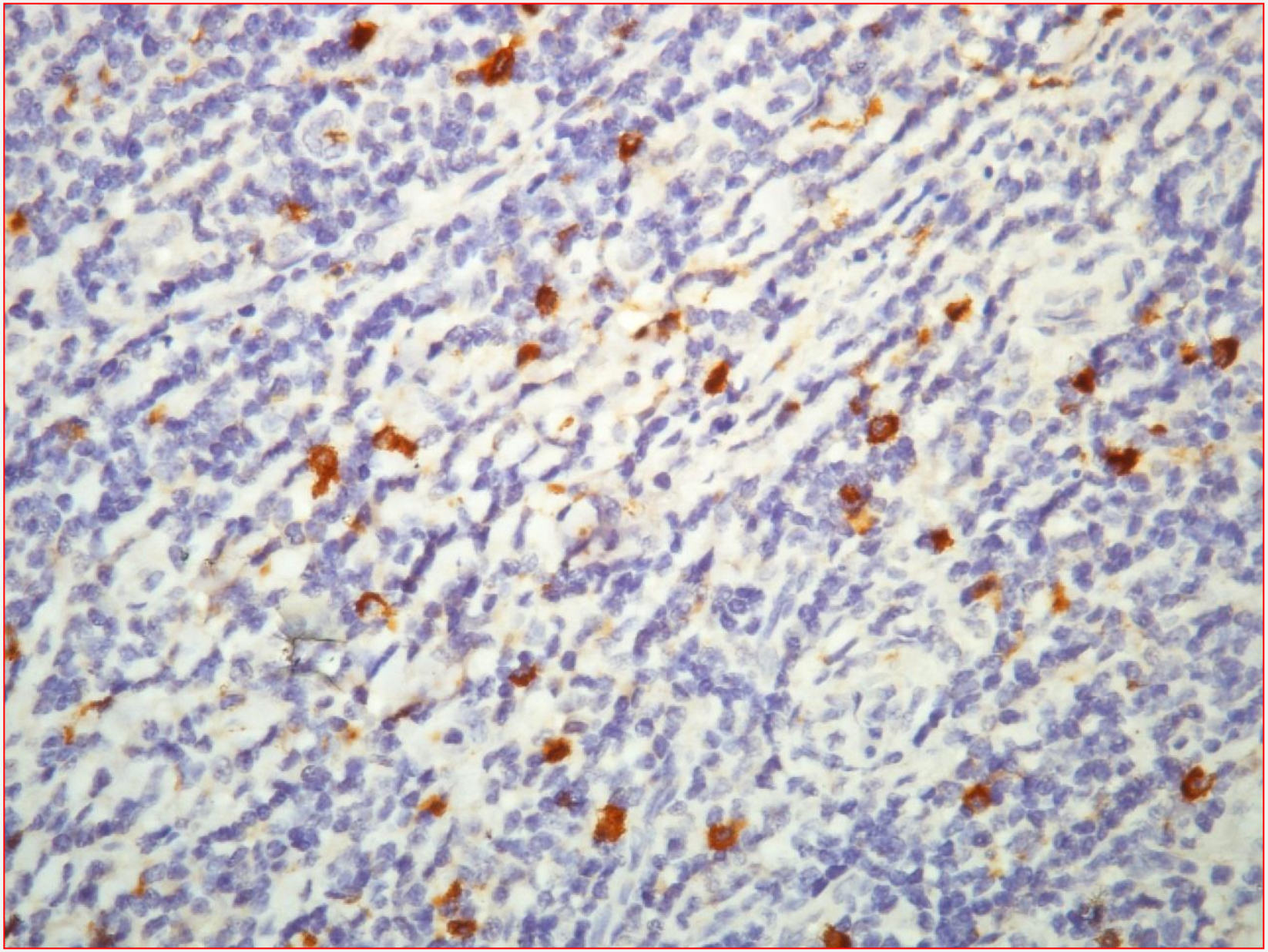

Células em apoptose (caspase 3)

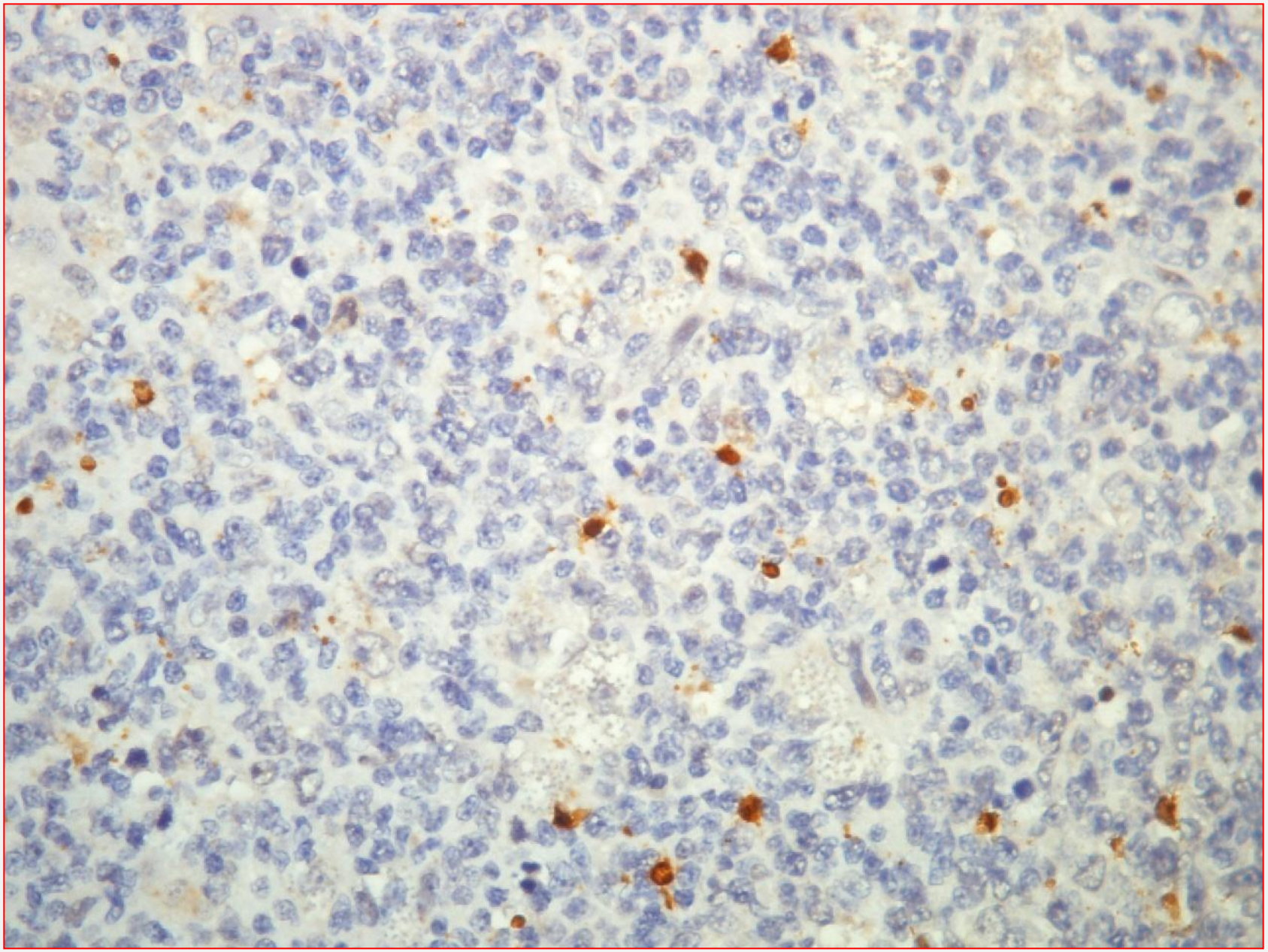

Análise quantitativa das células de Langerhans

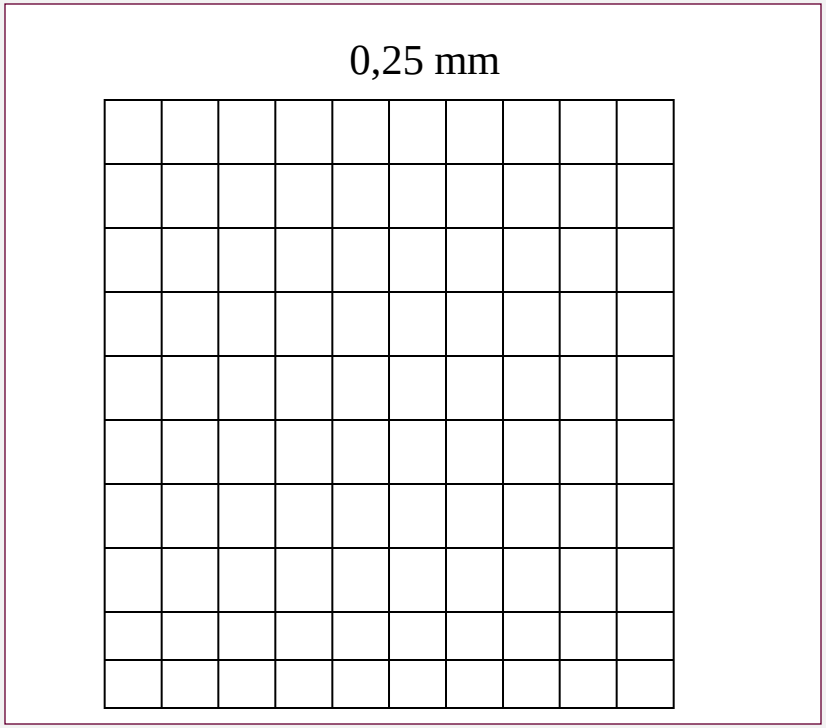

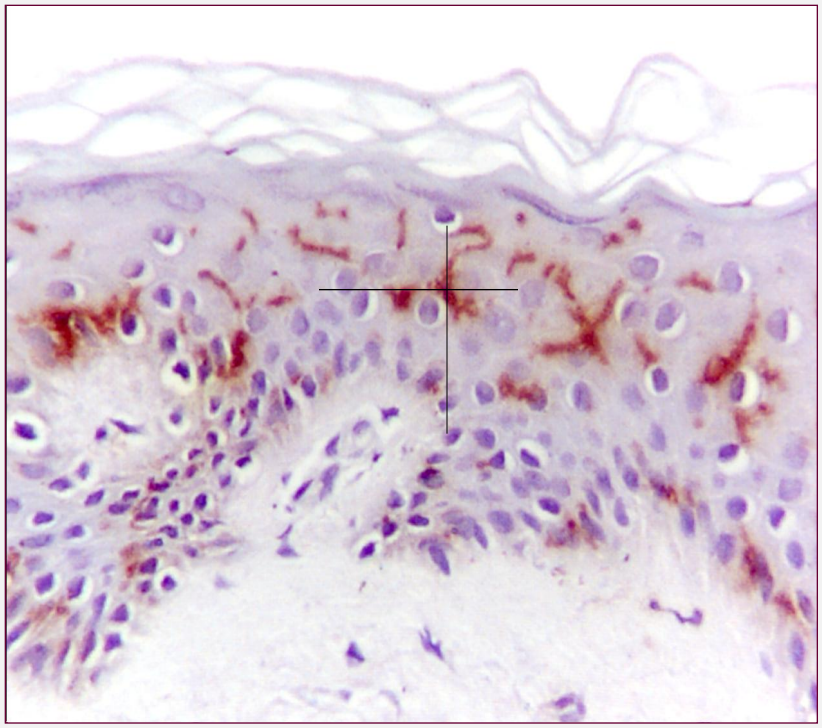

Fração de área epidérmica

10 µm

Análise quantitativa

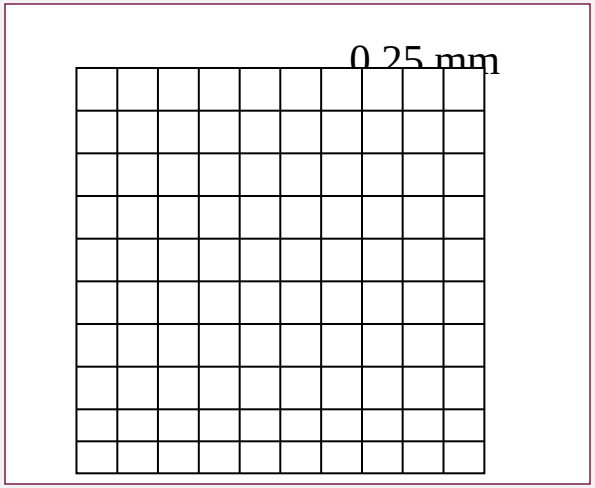

- **1cm = 10 mm**
- **10 mm / 40 (aumento do microscópio) = 0,25**

- **No aumento de 400x:**
- **Para quantificação em 9 campos:**
- **Ex: 900 células / 9 = média de 100 células por campo.**

- **0,25 x 0,25 = 0,0625 = área do gratículo (campo)**

- **100/0,0625 = 1600 células/mm^2**

Esquema da reação de dupla-marcação imunohistoquímica

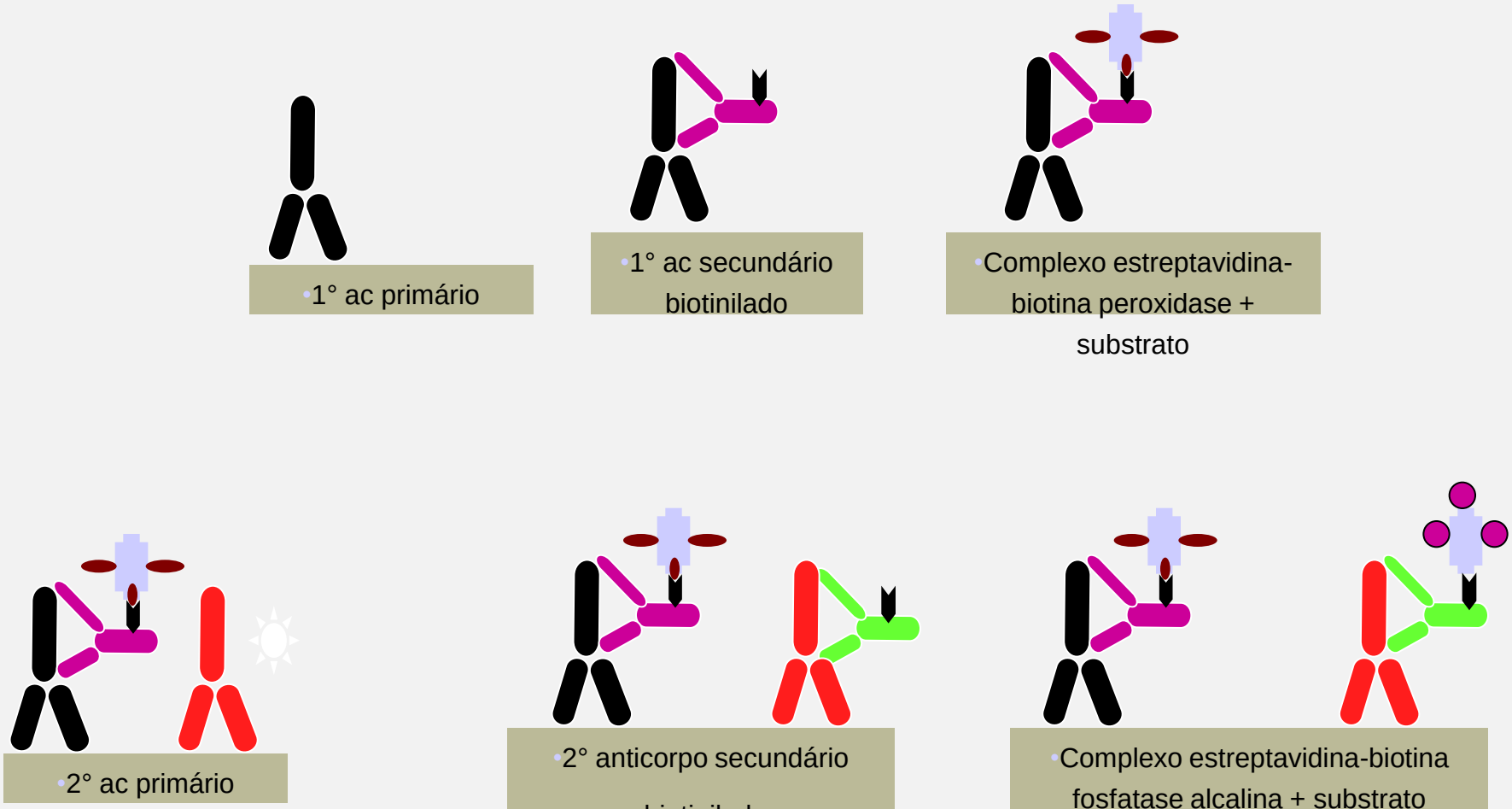

Reação imuno-histoquímica de dupla-marcação (CD4-azul/IL17-marrom)

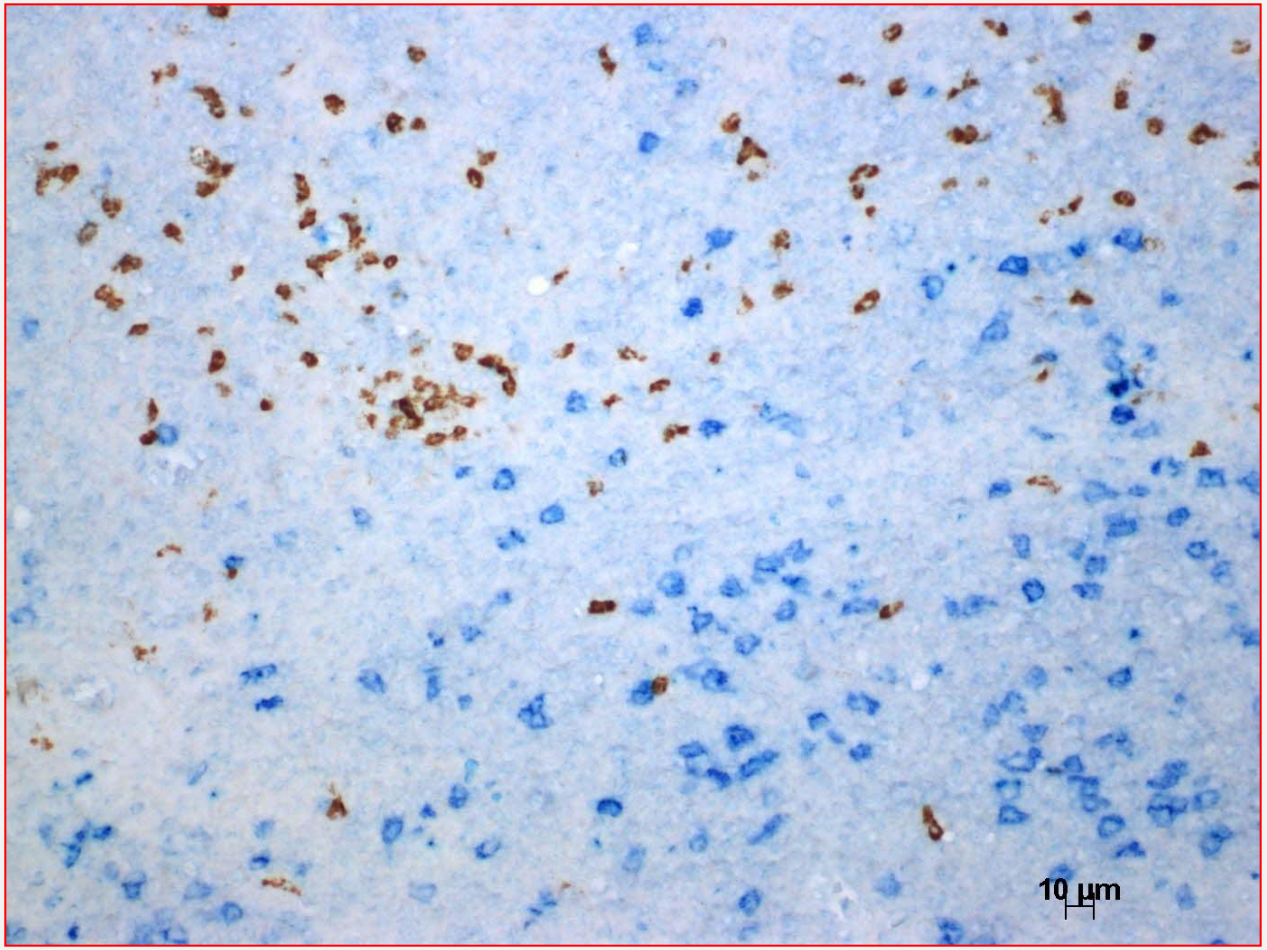

Paracoccidioides brasiliensis no citoplasma de dendrócitos dérmicos FXIIIa+

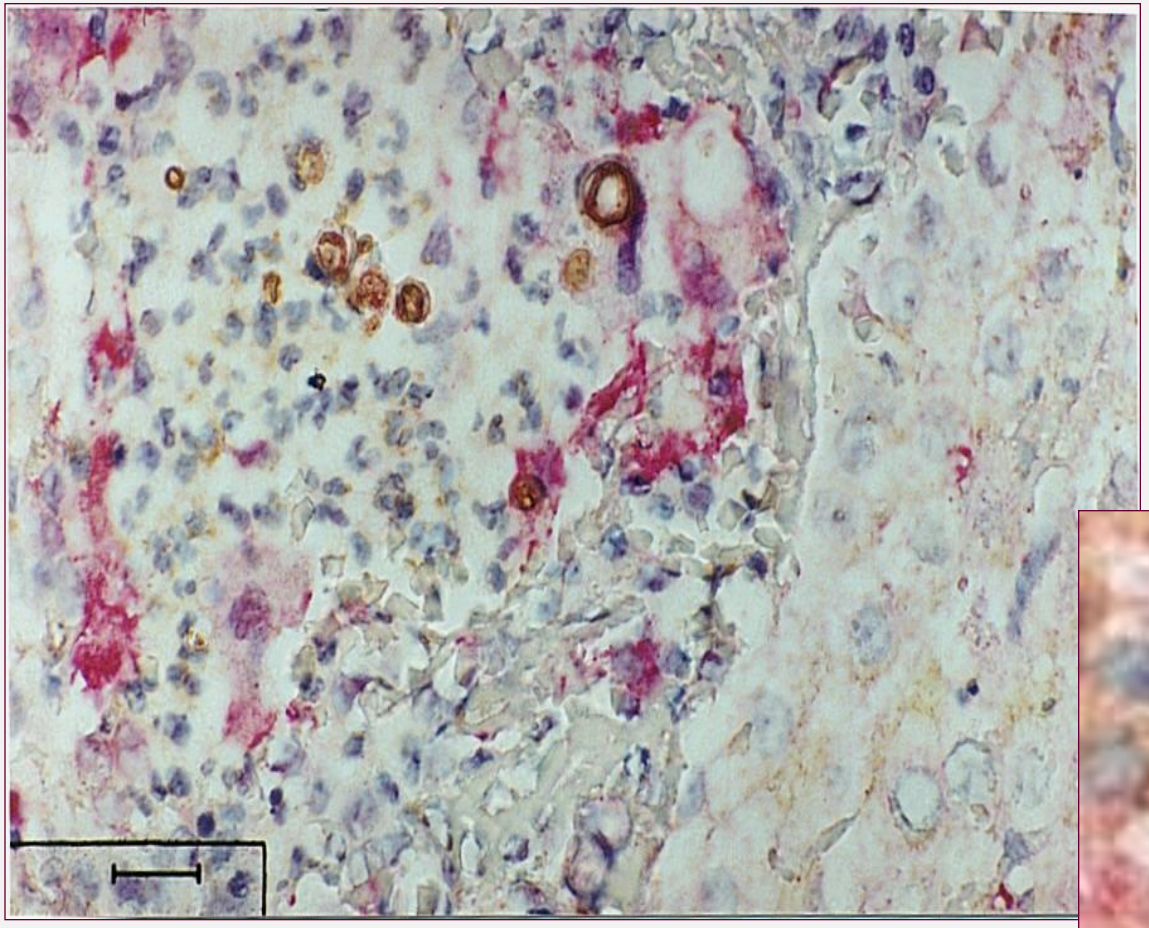

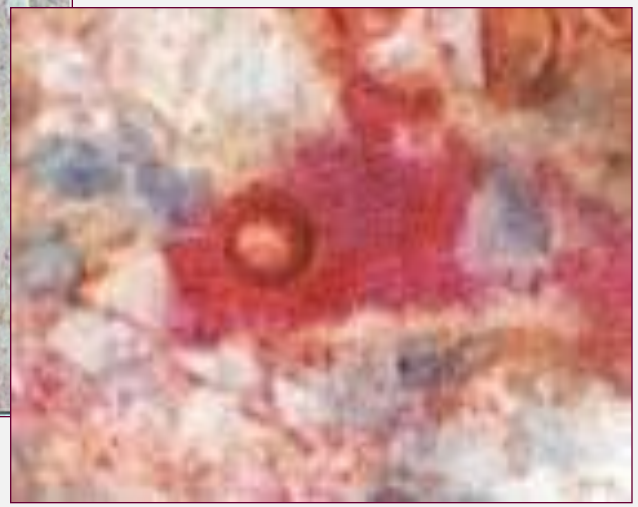

- (Pagliari, Sotto) Correlation of factor XIIIa+ dermal dendrocytes with paracoccidioidomycosis skin lesions
- Medical Mycology 2002; 40:407-410

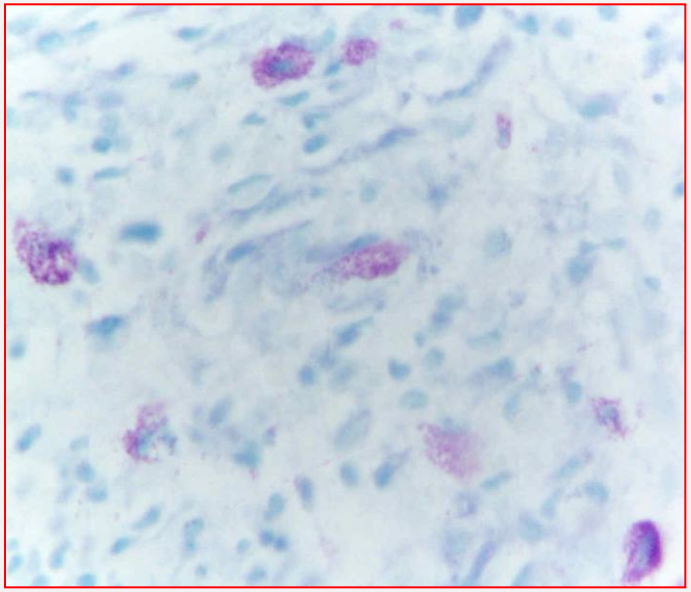

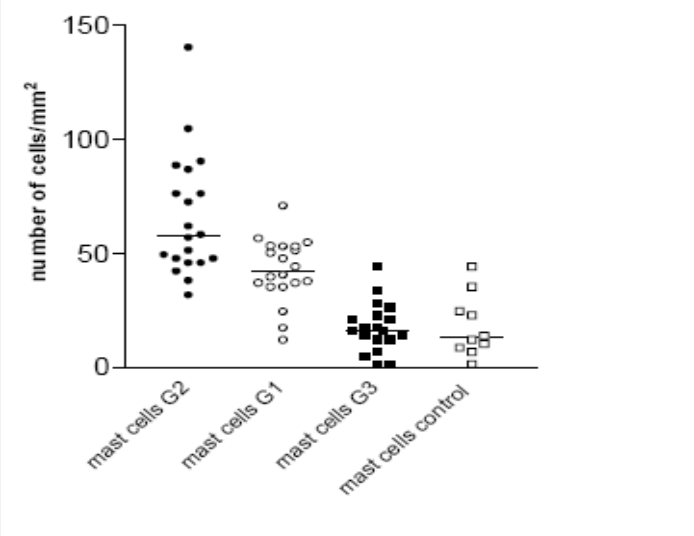

- **Paracoccidioidomicose – Mastócitos**

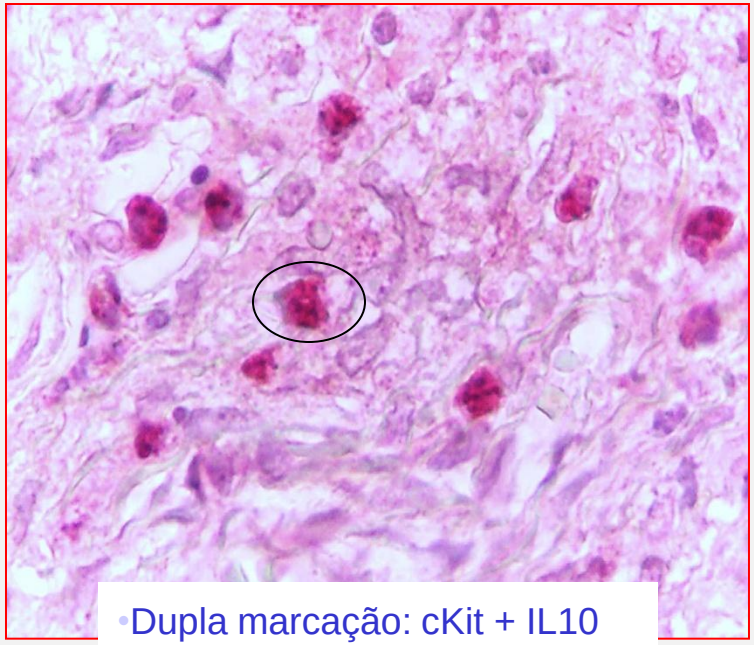

- Dupla marcação: cKit + IL10

- Mycopathologia. 2006 Nov;162(5):331-5. Role of mast cells as IL10 producing cells in paracoccidioidomycosis skin lesions. Pagliari C, Fernandes ER, Guedes F, Alves C, Sotto MN.

Lesão de mucosa oral - paracoccidioidomicose

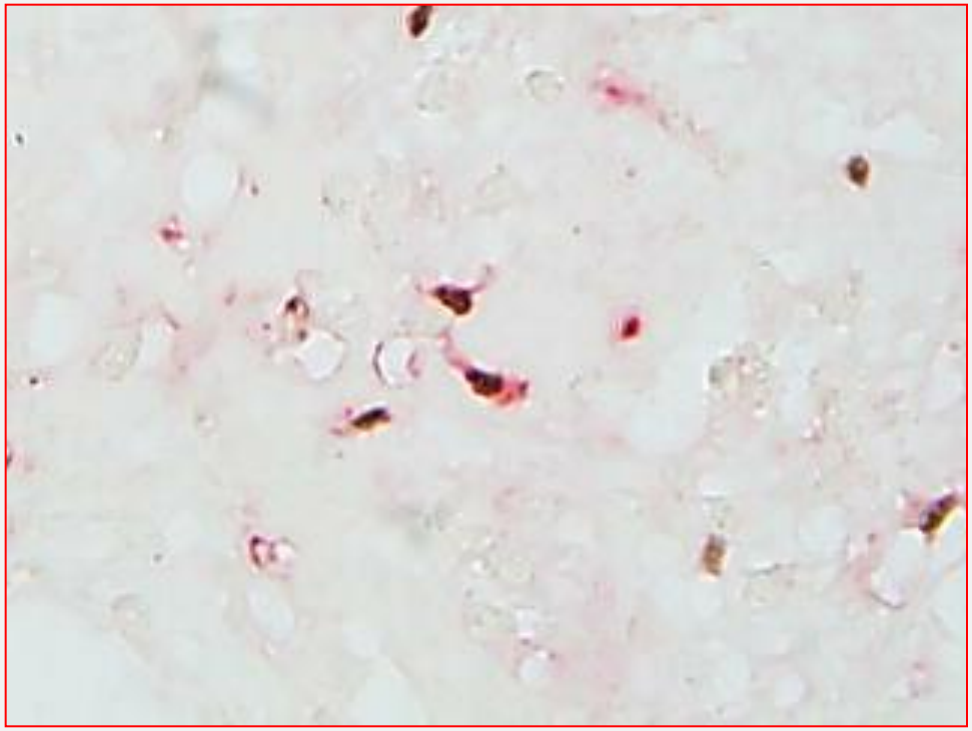

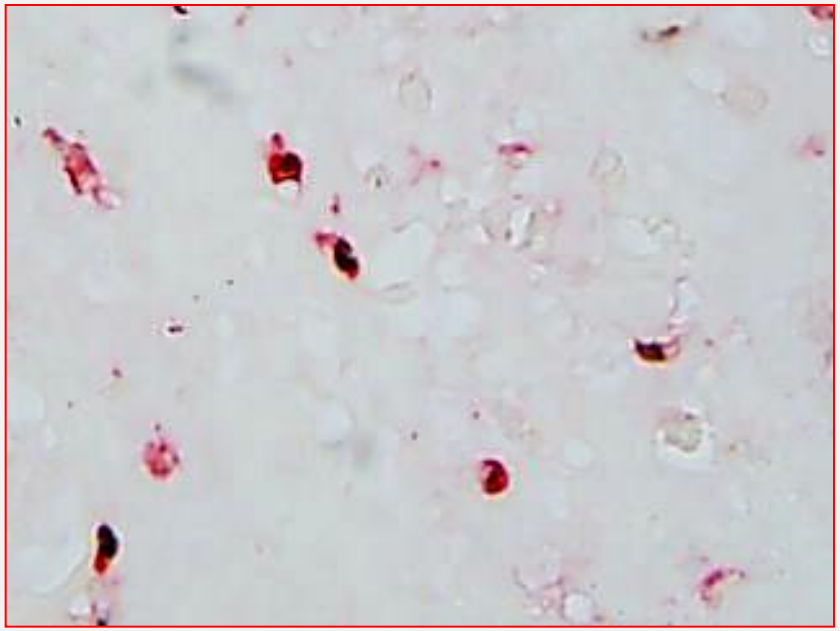

- Foxp3 – negro
- CD25 - vermelho

Lesão de pele - Dupla-marcação Leishmania e dendrócitos FXIIIa+

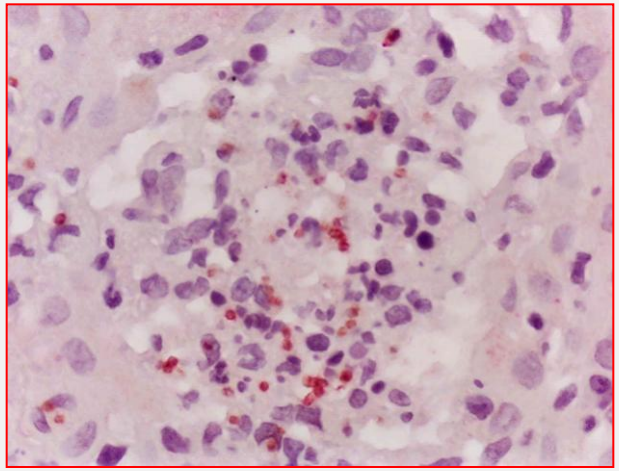

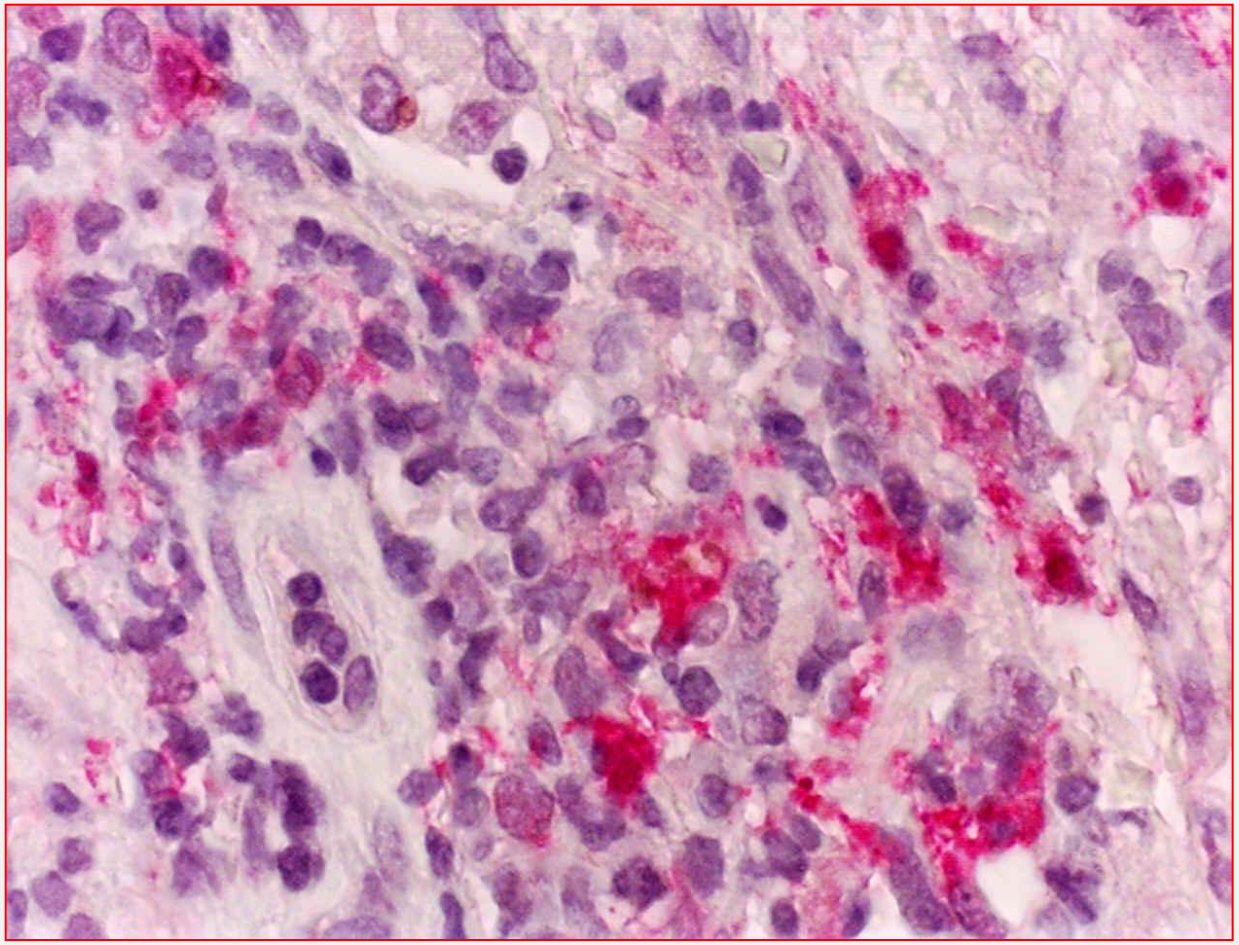

Lesão de pele – cromomicose

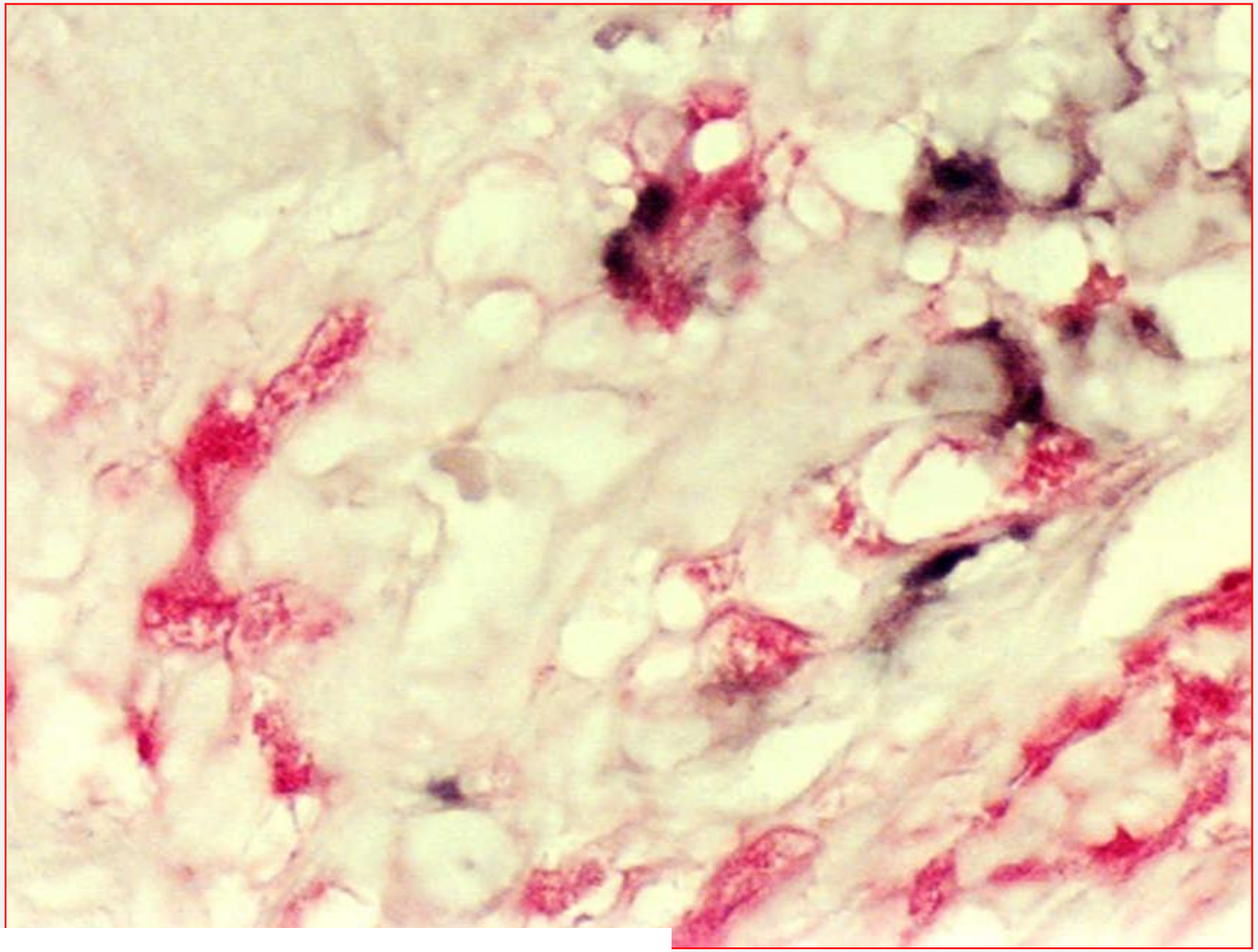

- *F.pedrosoi* (NBT-BCIP - azul escuro)
- Fator XIIIa (vermelho)

Lesão de pele - cromomicose

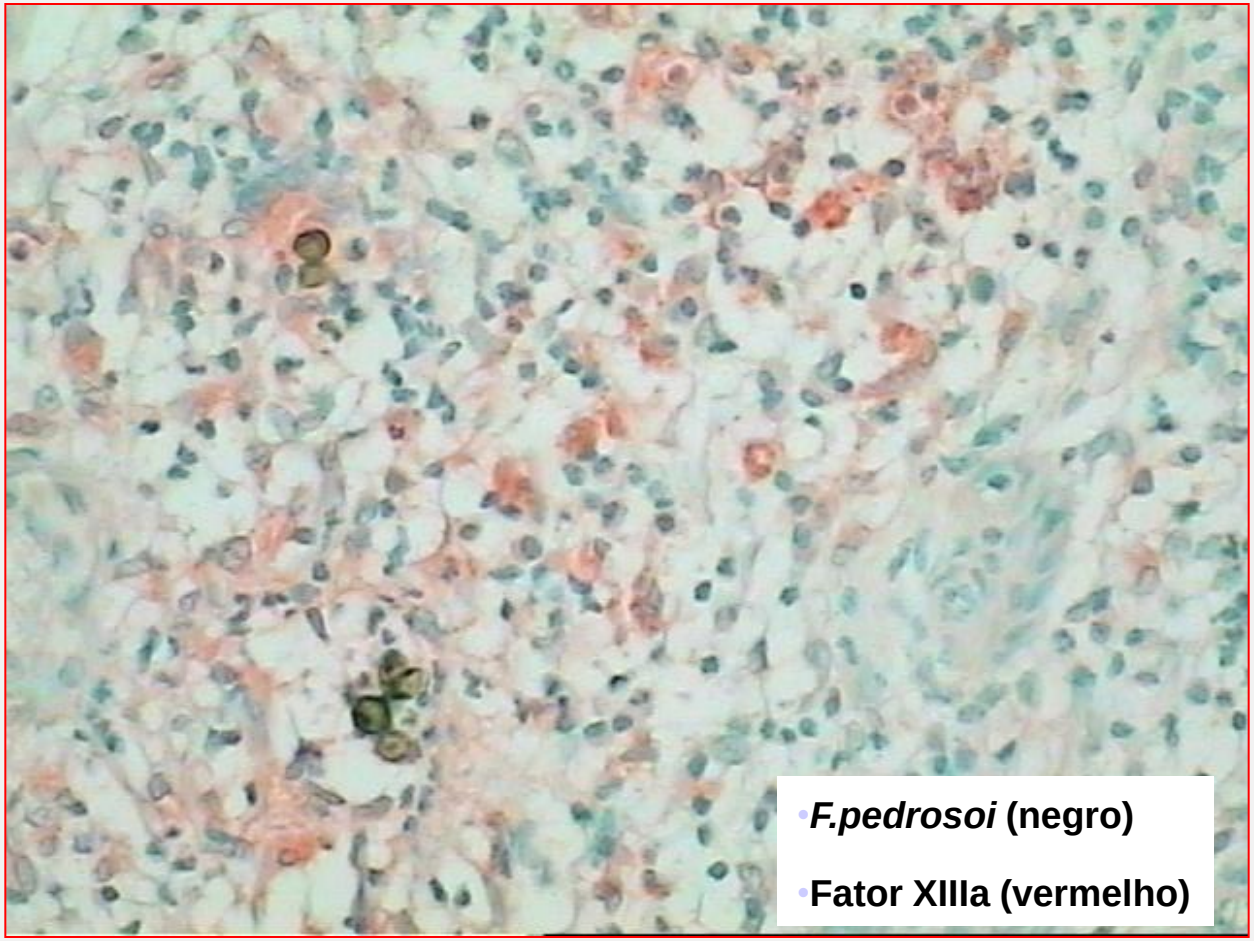

- J Cutan Pathol. 2004 Jan;31(1):14-8. Antigen distribution and antigen-presenting cells in skin biopsies of human chromoblastomycosis. Sotto MN, De Brito T, Silva AM, Vidal M, Castro LG.

Sarcoma de Kaposi
Lesão de pele - Dupla-marcação HHV8 e dendrócitos FXIIIa+

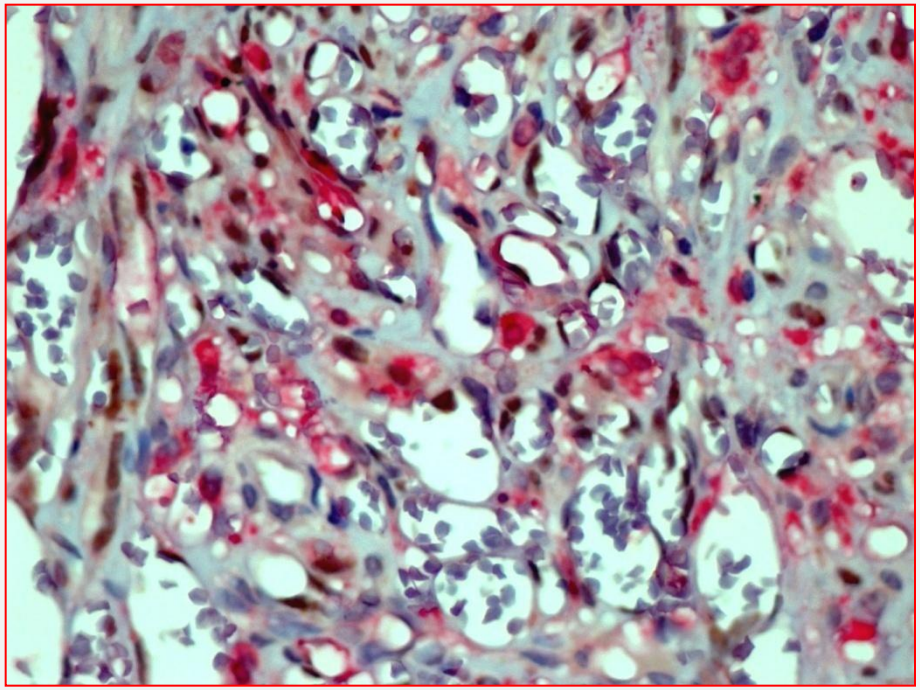

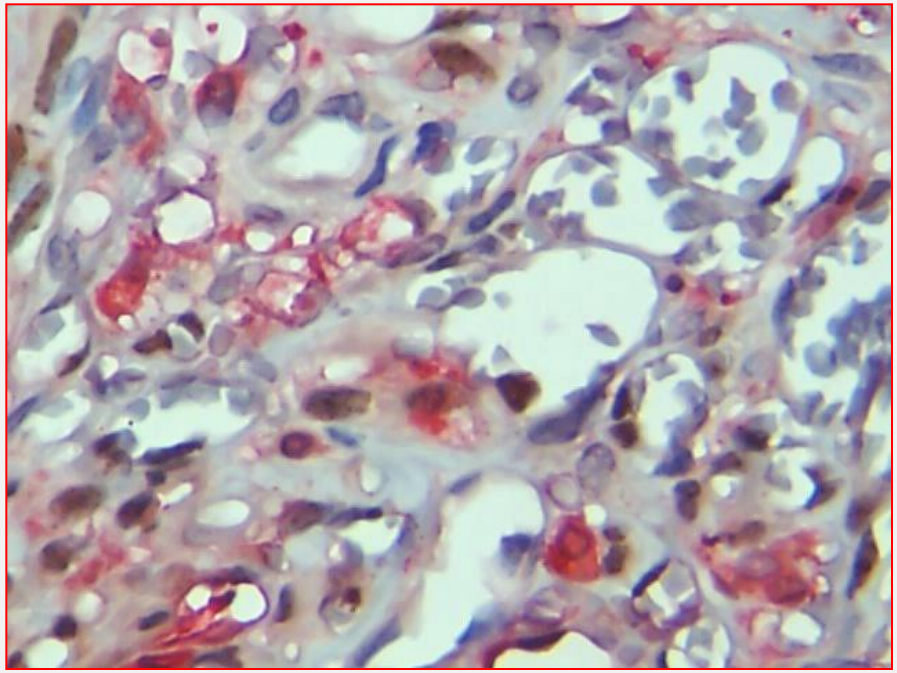

- Br J Dermatol. 2008 Sep;159(4):839-46. The effects of human herpesvirus 8 infection and interferon-gamma response in cutaneous lesions of Kaposi sarcoma differ among human immunodeficiency virus-infected and uninfected individuals. Guedes F, de Andrade HF Jr, Fernandes ER, Tuon FF, Brasil RA, Pagliari C, Duarte MI.

Sarcoma de Kaposi
Lesão de pele - Dupla-marcação HHV8 e dendrócitos FXIIIa+

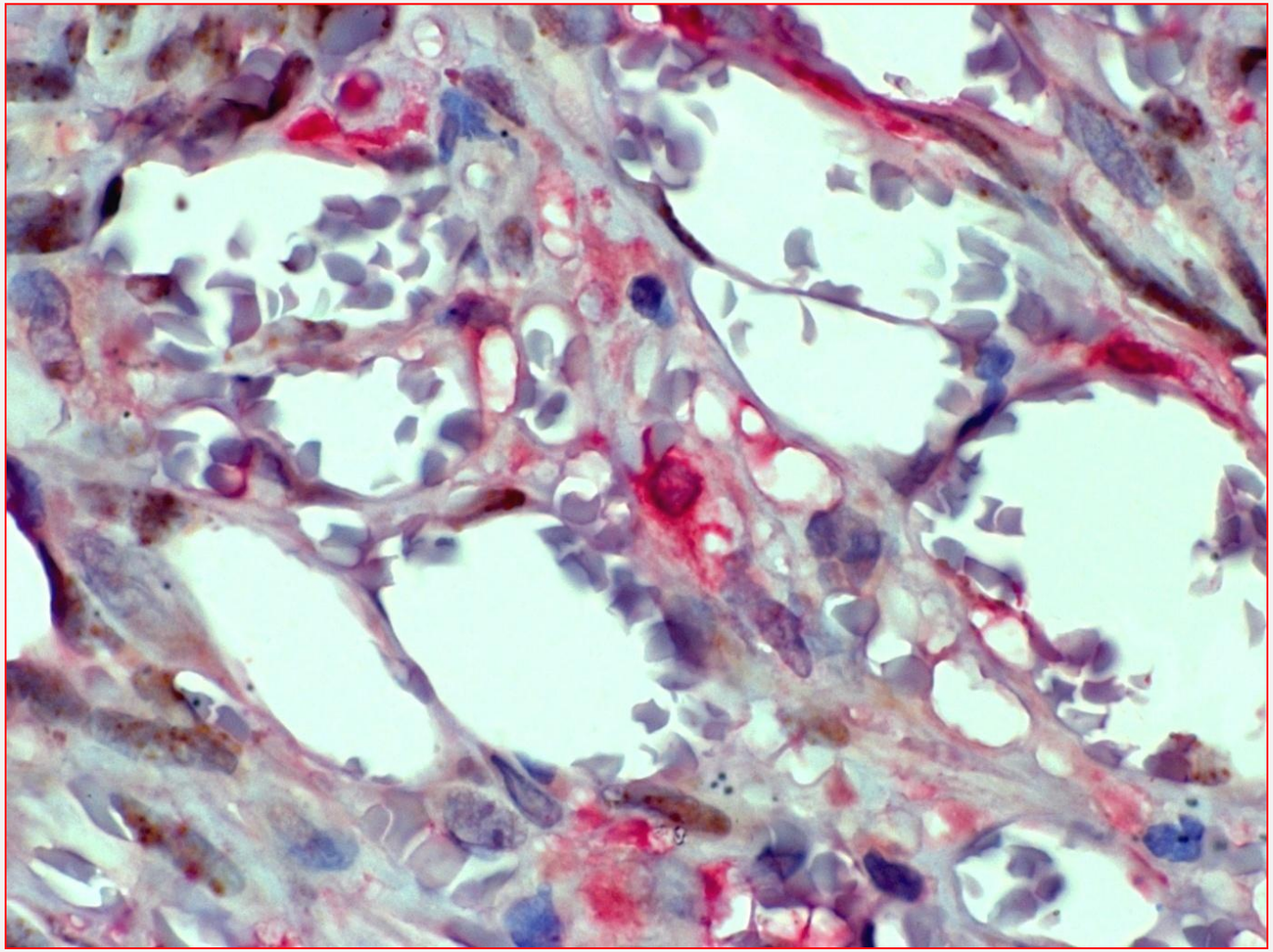

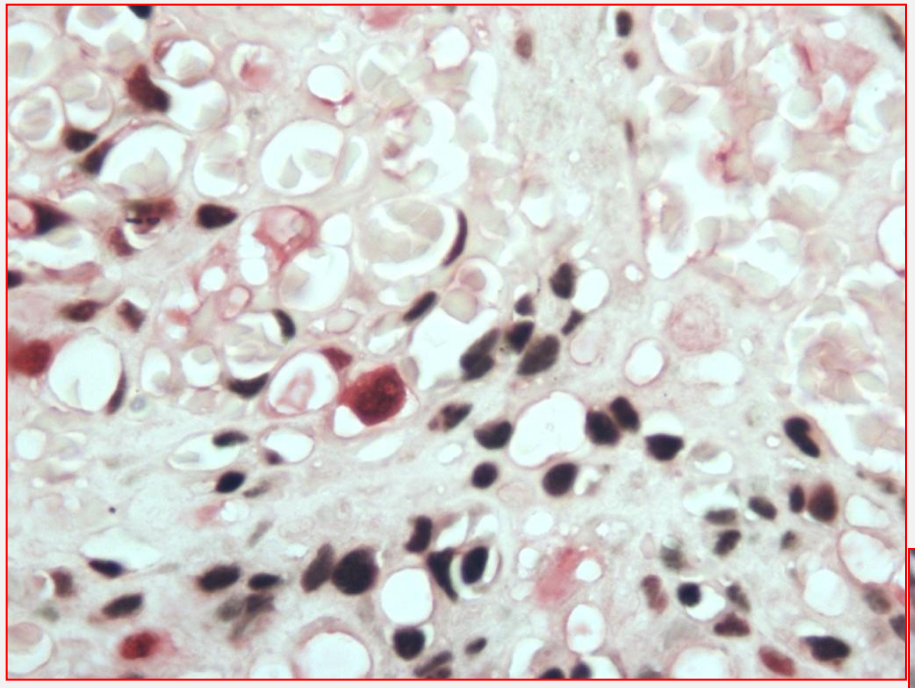

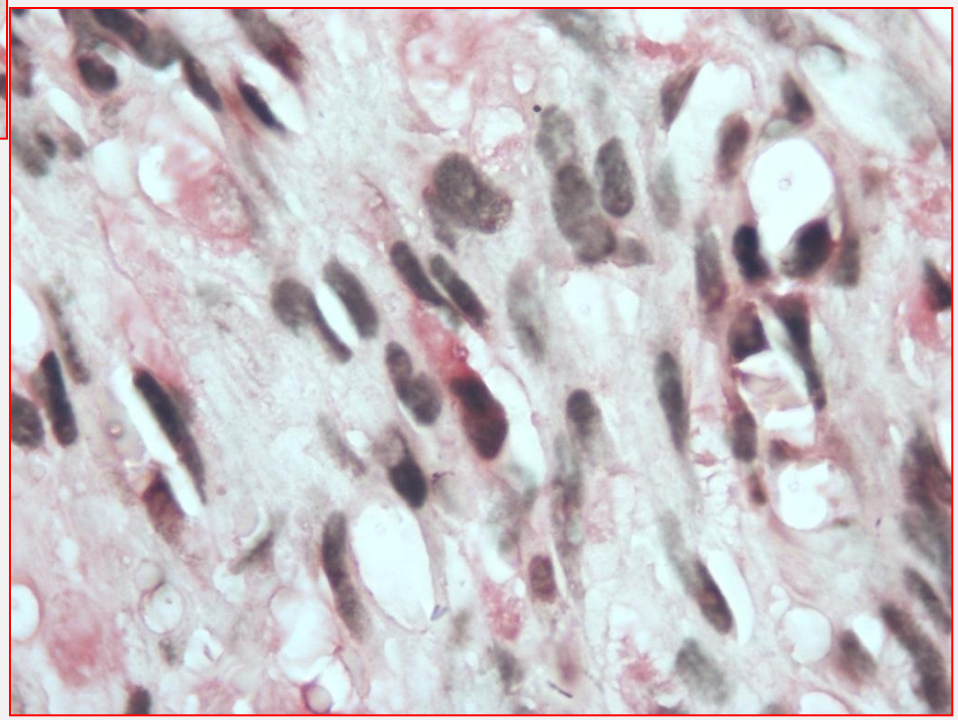

- **SK – HHV8 e CD303**

Raiva humana
Lesão em SNC - Dupla-marcação GFAP e vírus da raiva

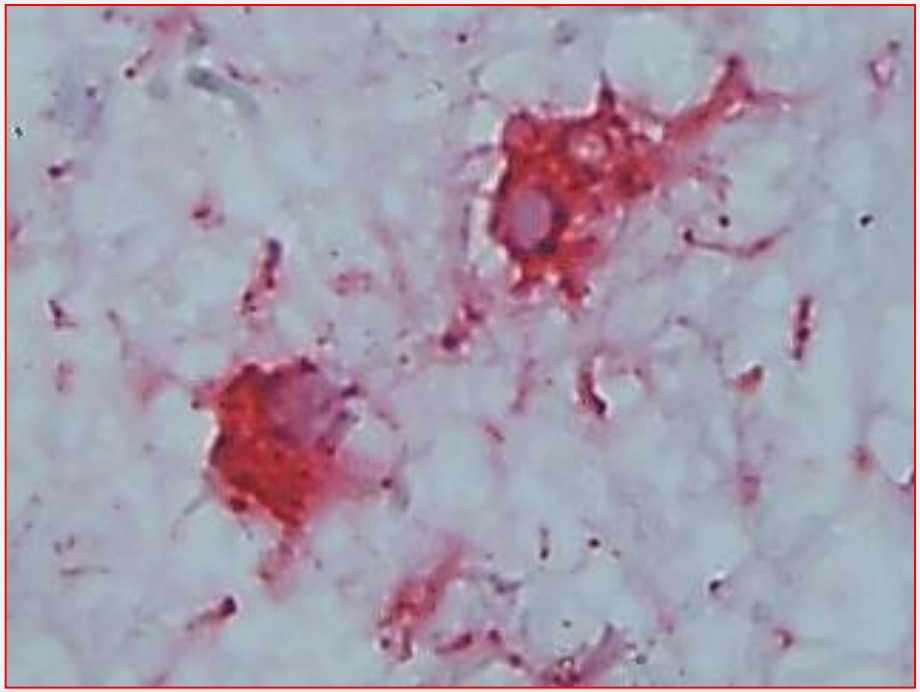

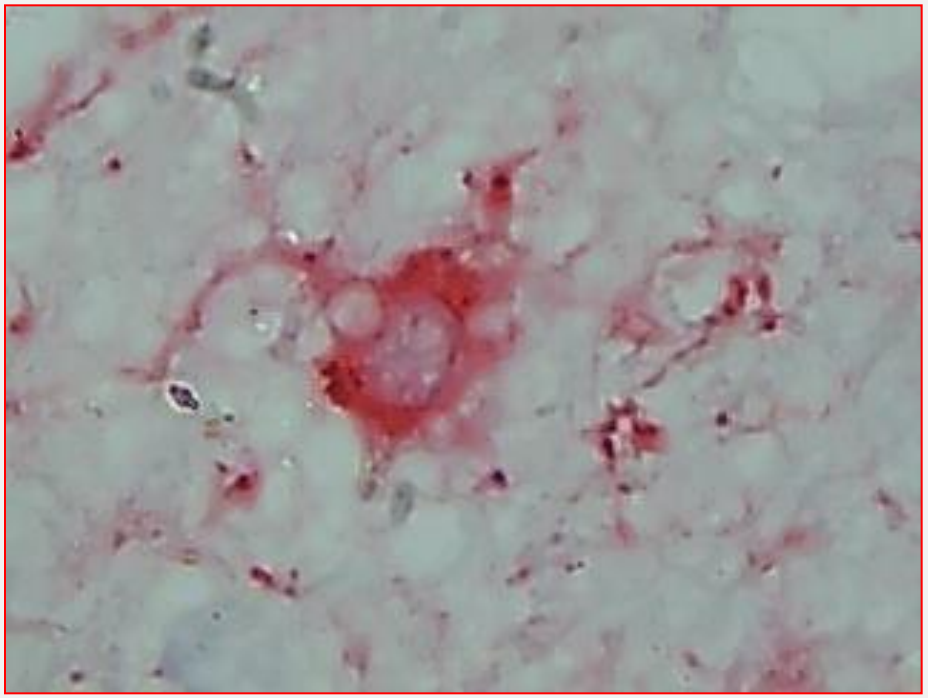

- Astrócitos – vermelho
- Virus da raiva - negro

Papilomavirus
Lesão de vulva - Dupla-marcação HPV (Hibridização *in situ*) e FXIIIa

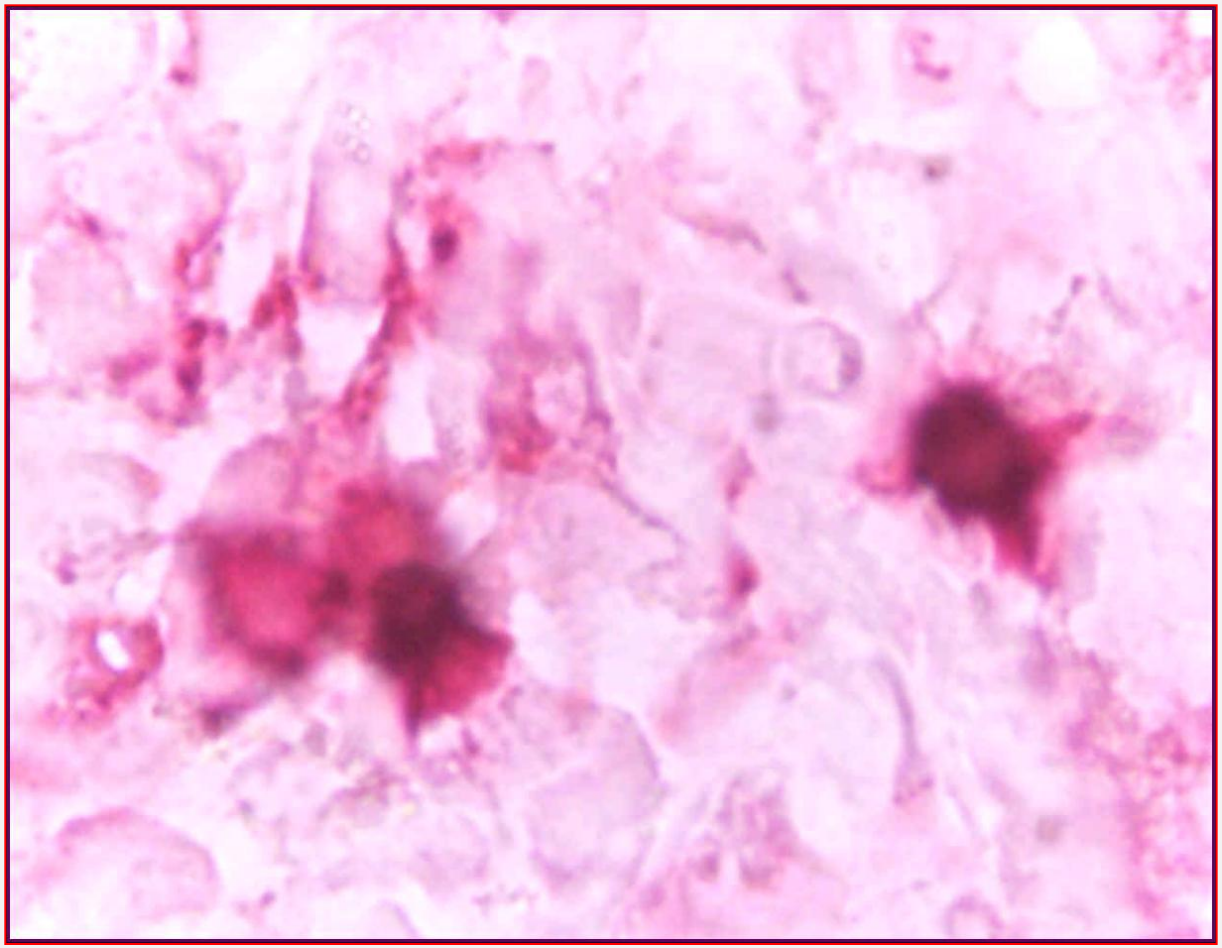

- Acta Derm Venereol. 2008;88(4):391-3. Interaction of human papillomavirus DNA with factor XIIIa-positive dermal dendrocytes in vulvar lesions. Pereira NV, Pagliari C, Fernandes ER, Guedes F, Sotto MN, Duarte MI.

Hanseníase multibacilar

- Vasos – negro
- Bacilo – vermelho (Faraco)

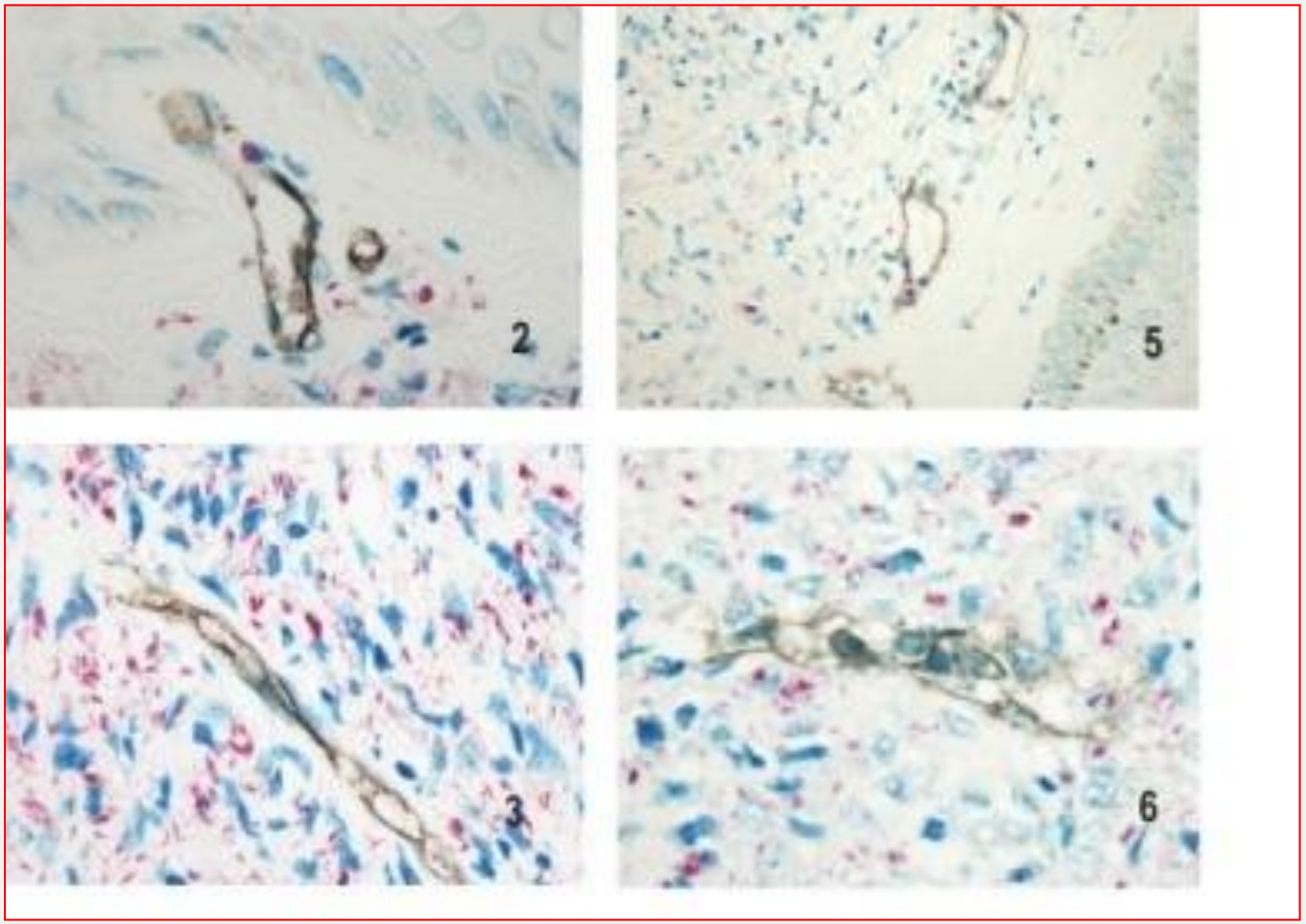

- **Interação de células endoteliais linfáticas e sangüíneas com o *Mycobacterium leprae* nas lesões cutâneas de hanseníase multibacilar.**

- Felipe Weisshaupt Stegun1, Profa Dra. Érika Pereira da Costa2, Profa. Dra. Mirian Nacagami Sotto3.

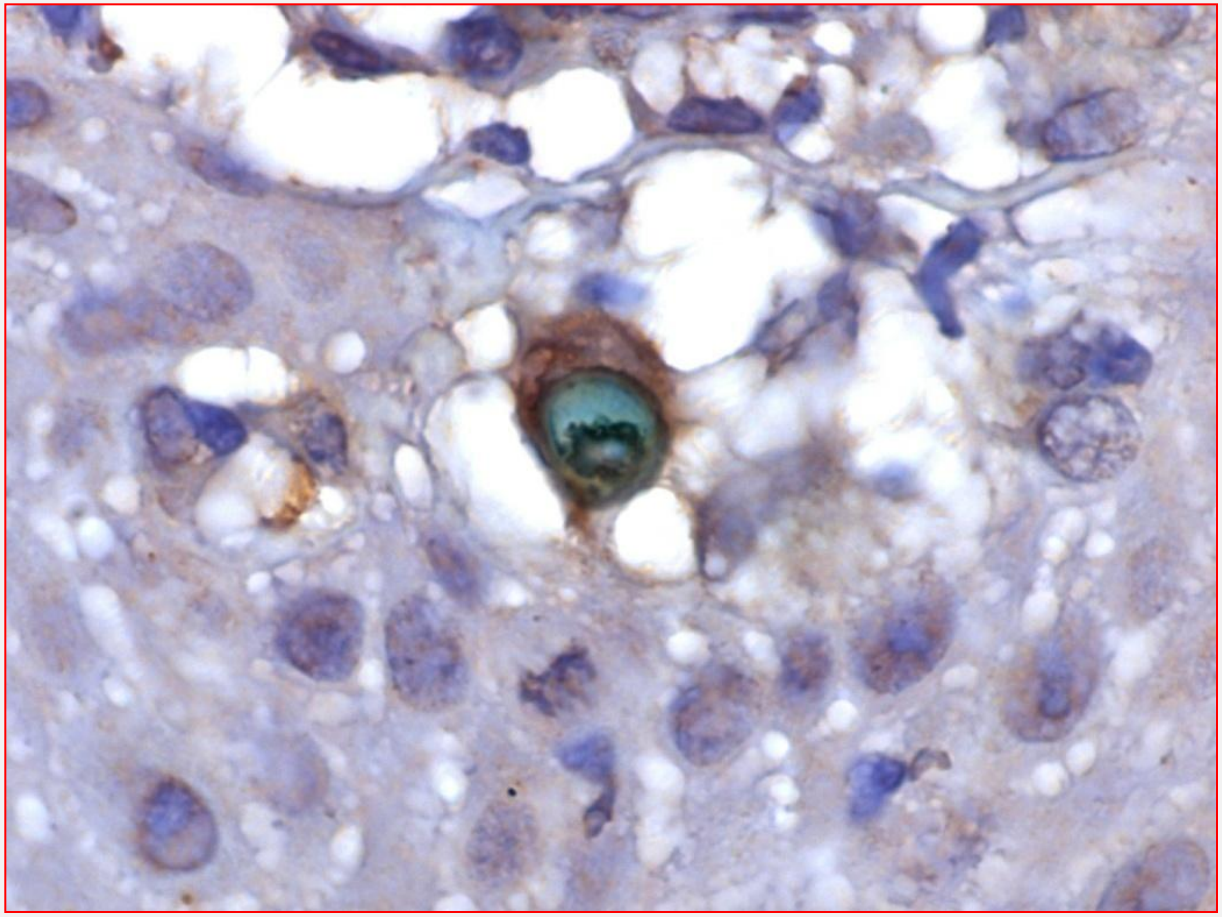

Monografia de conclusão de curso do aluno Wellington Luiz F. Silva – programa de aprimoramento profissional LIM HCFMUSP

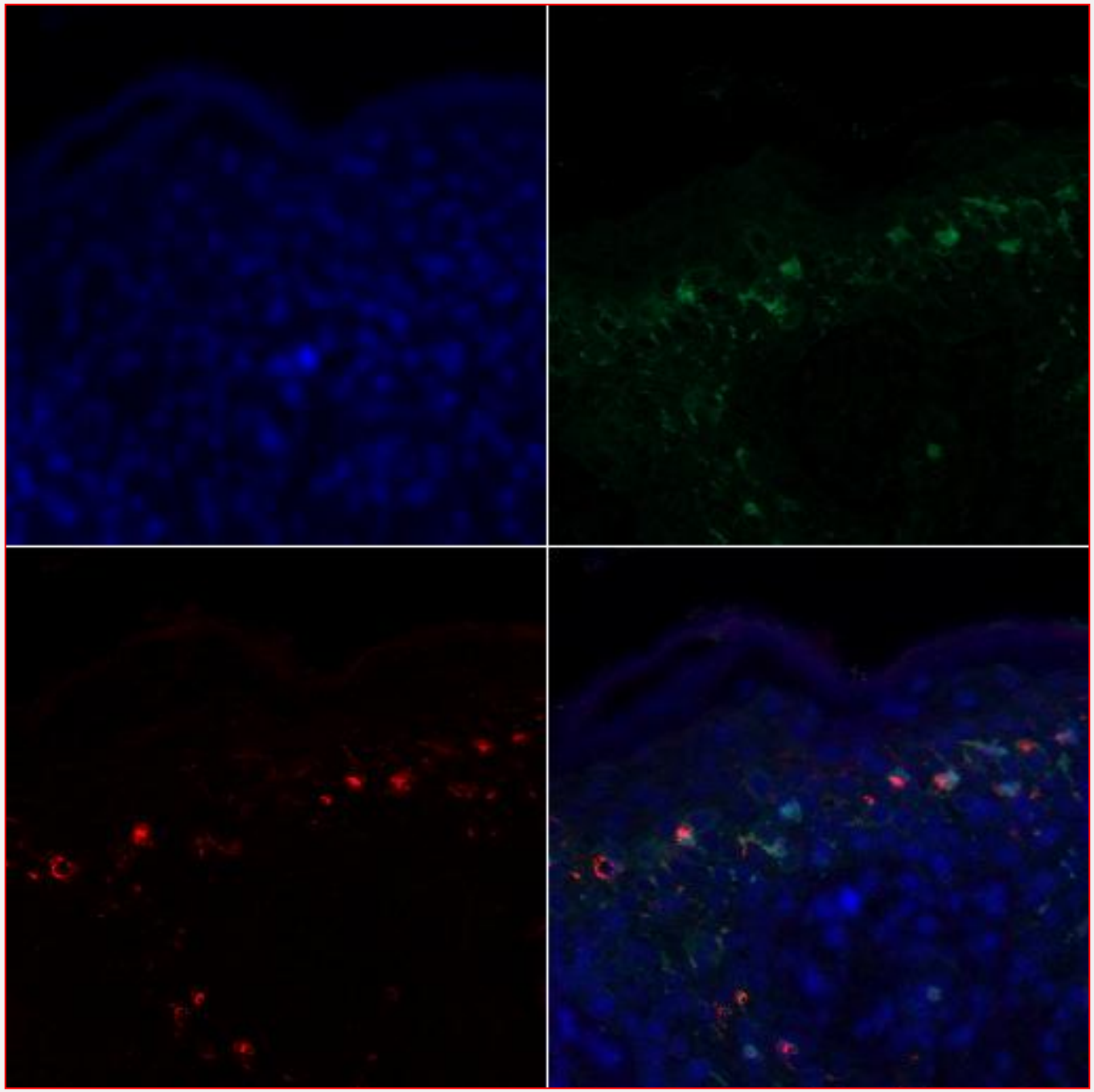

- S100 - verde
- CD207 - laranja

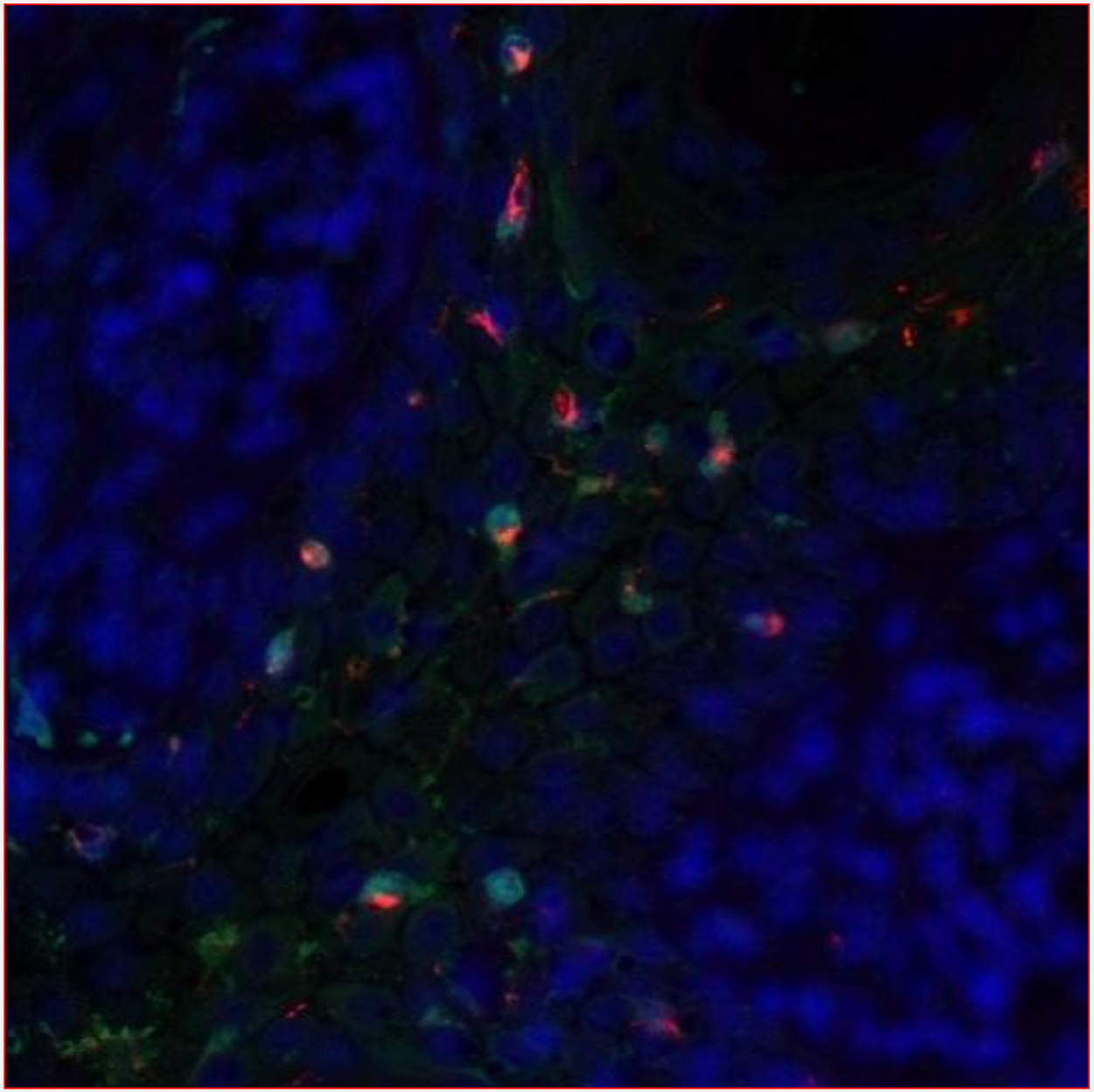

- S100 - verde
- CD207 - laranja

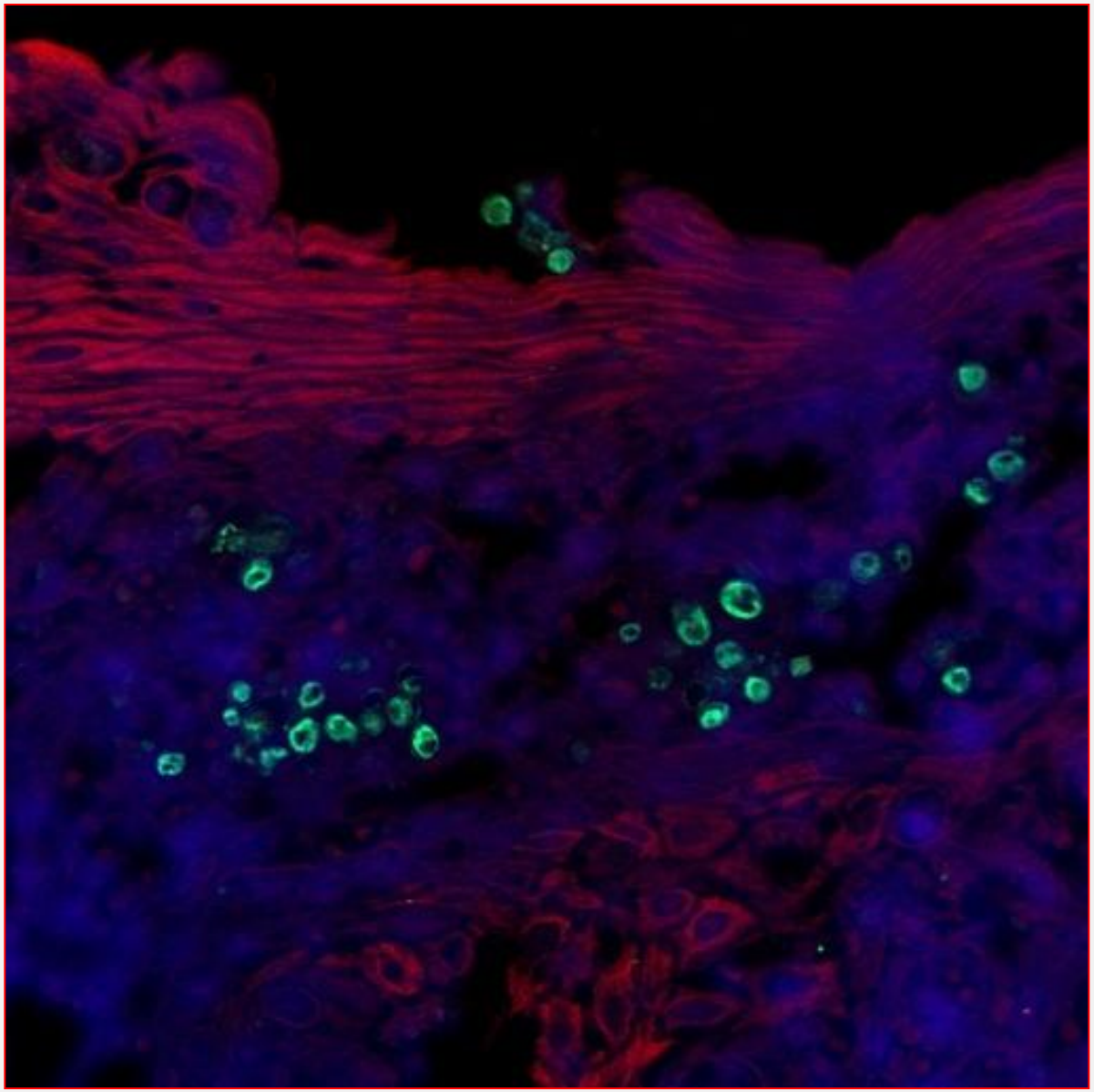

- Queratinócitos – laranja
- *P. brasiliensis* - verde

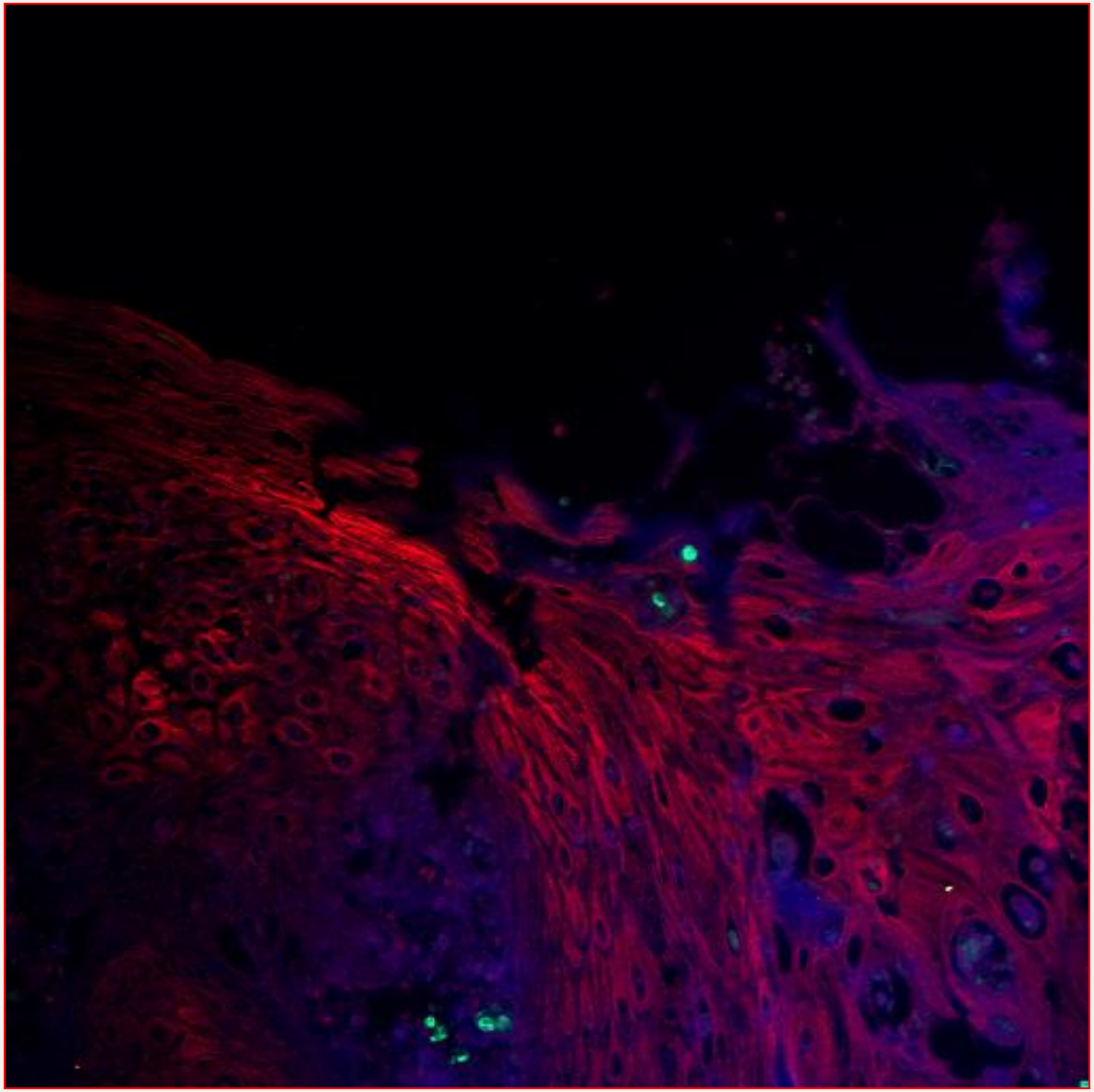

- Queratinócitos – laranja
- *P. brasiliensis* - verde

Obrigada!

cpagliari@usp.br